

# Association between human papillomavirus (HPV) and the oral squamous cell carcinoma: a systematic review

## *Associação entre o papilomavírus humano (HPV) e o carcinoma de células escamosas oral: uma revisão sistemática*

Marcos Antonio Pereira de Lima<sup>1</sup>; Cláudio Gleidiston Lima da Silva<sup>2</sup>; Sílvia Helena Barem Rabenhorst<sup>3</sup>

### ABSTRACT

The human papillomavirus (HPV) is an epitheliotropic agent whose high-risk genotypes have a well-established link with the development of cervical cancer. Although the relation of HPV to the oral squamous cell carcinoma (OSCC) has been studied since the beginning of the 1980s, its role in the oral carcinogenesis and the probable underlying molecular mechanisms are still not fully elucidated. We performed a systematic review of the worldwide scientific literature, published until the preparation of the present paper, concerning the association of HPV with OSCC, scrutinizing the samples, prevalence levels, the techniques utilized and relevant findings of the studies. The results showed that HPV is associated with approximately one quarter of OSCCs. Another interesting feature is the distinct pattern of infection in these oral tumors, including the participation of genotypes that are uncommon in cervical malignant lesions, such as HPV-38, 44, 53 and 70. Equally interesting is the possibility of carcinogenic action without the occurrence of viral integration, verified by the high expression of messenger ribonucleic acid (mRNA) of E6 and E7 from high-risk genotypes in cases whose virus remain in the episomal form. These findings support the assumption of HPV involvement in the genesis of OSCC, whereas warn about the possibility of unexpected viral behaviors that sometimes are not perceived or understood due to the technological limitations of the time and to the shortage of studies with the adequate approaches.

**Key words:** HPV; oral cancer; squamous cell carcinoma.

### INTRODUCTION

Oral cancer is a serious worldwide public health problem, with high incidence and mortality rates. According to data from the International Agency for Research on Cancer (IARC), approximately 263,900 new cases and 128,000 deaths by cancer of the oral cavity are estimated to have occurred in the world in 2008<sup>(22)</sup>. Among the malignant tumors of this anatomic site, more than 90% are oral squamous cell carcinomas (OSCC). Several risk factors are related to oral cancer, with the main being: tobacco use, alcohol consumption, and infection by high-risk genotypes of human papillomavirus (HPV)<sup>(41)</sup>.

HPV is an epitheliotropic virus implicated in the development of skin warts and papillomatous lesions in mucosae<sup>(46, 55)</sup>. Nowadays, more than 100 HPV genotypes are known, and based on their potential for induction of malignant transformation, the several genotypes are classified as “low risk” and “high risk” for the development of genital malignancy<sup>(24)</sup>. Structurally, this virus is characterized by a non-enveloped icosahedral capsid, with circular double-stranded deoxyribonucleic acid (DNA) genome, approximately 8,000 base pairs (pb) long<sup>(33, 40)</sup>. Its genome may encode six early and two late genes. Among the early genes, E6 and E7 deserve attention, because their homonymous products, among other effects, promote the degradation of tumor suppressors p53

First submission on 11/06/13; last submission on 13/11/13; accepted for publication on 19/11/13; published on 20/02/14

1. Doctorate in Biotechnology in Health from Rede Nordeste de Biotecnologia (Renobio)/Universidade Federal do Ceará (UFC); master's degree in Medical Microbiology from UFC; professor of Medical Microbiology at the Medical School of UFC.

2. Doctorate in Pharmacology from UFC; master's degree in Pathology from UFC; assistant professor of Pathology and Bioethics at the Medicine School of UFC.

3. Post-doctorate in Molecular Genetics from the University of Colorado Health Sciences Center – Medical Oncology; doctorate in Biological Sciences from Universidade Estadual Paulista Júlio de Mesquita Filho (UNESP); master's degree in Biological Sciences from UNESP; associate professor IV at UFC.

and pRb, respectively, an event considered crucial for the neoplastic transformation of infected cells<sup>(26, 35, 36, 39)</sup>.

The mechanism that makes a high-risk HPV induce the malignant progression of previously benign lesions is, primarily, this genotype capacity to integrate its genome to that of the host (viral integration). This provokes the break of a viral DNA segment that contains E2 gene, which, among other functions, inhibits the expression of E6 and E7 genes, culminating in the overexpression of E6 and E7<sup>(18, 40)</sup>. This cascade of events leads to excessive and unregulated cell proliferation, with involvement of repair mechanisms, which favors the accumulation of mutations and the occurrence of chromosomal aberrations, as well as apoptosis inhibition<sup>(12, 26)</sup>.

The relationship between HPV and OSCC was first suggested in 1983 by Syrjänen *et al.*<sup>(49)</sup>, when they discovered koilocytotic atypias in malignant oral lesions by optical microscopy. But the presence of viral DNA was only confirmed two years later, by means of *in situ* hybridization (ISH)<sup>(29)</sup>. HPV infection in the oral cavity is associated with risky sexual behaviors, mainly to orogenital sex. However, mouth-to-mouth contact, vertical birth-transmission and autoinoculation resulting from chewing warts are also transmission modes of this virus to the oral mucosa<sup>(10)</sup>. The viruses isolated in OSCC are low-risk genotypes, including HPV-6, 11, 16, 18, 22, 31, 33, 35, 38, 58, 68, and 70<sup>(51)</sup>. Nevertheless, in around 80% of the cases of infected oral squamous carcinomas, the identified genotypes were HPV-16/18. Co-infections with two HPV genotypes have been reported; the findings reveal that in these cases, neoplasms tend to occur, on average, a decade earlier than in individuals infected by a single genotype, or not infected<sup>(32)</sup>.

In spite of the methodological advances and the innumerable works developed since then, the role of HPV in oral carcinogenesis has not been fully elucidated. The several findings that reinforce the hypothesis of this virus involvement in oral neoplasia were followed by conflicting results. In this article, we reviewed the international scientific studies published until the preparation of this manuscript, concerning the association between HPV and OSCC, scrutinizing the sample characteristics, prevalence rates, the used techniques and the relevant study findings.

## MATERIALS AND METHODS

The articles used for the conduction of this systematic review were selected on Pubmed (<http://www.ncbi.nlm.nih.gov/pubmed>). The full versions of almost all the articles were retrieved either from that search engine or at the periodical portal of Coordenação de Aperfeiçoamento de Pessoal de Nível Superior (CAPES) (<http://www.periodicos.capes.gov.br/>). The descriptors used in the search

were: human papillomavirus, HPV, oral carcinoma, oral squamous cell carcinoma, and OSCC.

*In situ* approach studies were given preference in this review, having in mind the existence of a smaller number of works using *in situ* detection in oral carcinomas, when compared with those using amplification of genetic material, as well as the importance of these methods for assessing HPV role in tumors, because they allow for the precise localization of the virus in tissue.

The inclusion criteria for the original articles were: 1. discuss the detection of HPV in samples of oral carcinoma, involving *in situ* techniques; or 2. combine HPV detection, regardless of the used technique, with the expression of tumor markers strictly related to HPV tumorigenic pathways; or 3. compare HPV detection with that of another virus with recognized carcinogenic potential; or 4. point out aspects that may contribute to comprehension of viral involvement in oral carcinoma, such as case-control studies, viral expression assays and those of malignant transformation in oral epithelial cells. Exclusion criteria: 1. not investigate HPV presence; 2. discuss exclusively other neck and head carcinomas; 3. use only amplification of nucleic acid for HPV detection, with neither *in situ* approach, nor assessment of tumor markers or the presence of another virus.

Based on the established criteria, we retrieved 41 articles, including the first reports, so that the current review comprises works published from 1983 to June 2013, in English and Spanish. In the development of this paper we also considered meta-analyses, which encompass information about virus detection through genetic amplification techniques, and review articles to deepen the discussion.

## RESULTS AND DISCUSSION

The **Table** provides a list of studies carried out in the last three decades around the world and their results as to HPV detection in oral carcinomas, highlighting those that used *in situ* methods. The average prevalence observed in those studies was approximately 25%, ranging from 0% to 100%. The works that displayed higher prevalence rates, in general, used the ISH technique with a biotinyl-tyramide-based detection system, or the *in situ* polymerase chain reaction (PCR) technique, which is a PCR followed by ISH, both steps performed on slide. We detected a shortage of studies on OSCC correlating HPV detection with the expression of strictly related tumor markers, from which little can be inferred. Also, there are few works assessing exclusively non-smoking and non-drinking patients, in which the average prevalence was discreetly higher (29%). We found no case-control studies investigating the relationship between HPV and the occurrence of OSCC.

**TABLE – Summary of studies, grouped by world region, assessing HPV association with oral carcinomas, highlighting those using *in situ* approaches**

Country	Techniques	Target	Positive cases (em OSCC)	Stained cell type	Genotypes	Observations	Ref.	Year
Japan	PCR	HPV	6/50 (12%)	–	HPV-16, 31, 58, 61	–	18	2011
	IHC	p16	8/50 (16%)	Tumoral				
	ISH	HPV	6/23 (26%)	Tumoral	–	Just in verrucous carcinomas	11	2008
	PCR		11/23 (48%)					
	<i>In situ</i> PCR	HPV	8/8 (100%)	Tumoral	HPV-16, 18, 22, 38, 70	–	24	2007
	ISH		0/8 (0%)					
	ISH-tyramide		2/8 (25%)					
	ISH-AT		6/8 (75%)					
	ISH-tyramide	HPV	0/2 (0%)	–	–	Just in lip tumors	42	2004
	PCR		5/27 (18.5%)		HPV-58, 75, 76			
Taiwan	ISH-tyramide	HPV	35/53 (66%)	Tumoral	Just HPV-38 was investigated	The mean p53(+) cells in HPV(+) tumors were higher than in HPV(-) and normal cells	23	2002
	PCR	HPV	35/53 (66%)					
	IHC	p53	–					
	ISH-tyramide	HPV	52/102 (50.9%)	Tumoral	HPV-6,11, 16, 18	HPV prevalence was higher in Okinawa sample 47/60 (78.3%) with ISH and PCR showing the same results	52	2000
	PCR	EBV	58/102 (56.8%)					
	<i>In situ</i> PCR		16/102 (15.6%)	Tumoral and lymphocytes				
	EBER1-ISH		13/16 (81.2%)					
PCR		62/102 (60.7%)						
<i>In situ</i> PCR	HPV	11/33 (33.3%)	Tumoral	HPV-16, 18	There was no difference in p53 expression between HPV(+) and HPV (-) groups	43	1995	
PCR dot blot		24/77 (31.1%)						
IHC	p53	6/26 (23%)						
Taiwan	<i>In situ</i> PCR	HPV	3/27 (11.1%)	Tumoral	HPV-11, 16, 18	–	8	2002
India	PCR	HPV	15/62 (24%)	–	HPV-16, 18	8 cases with HPV and EBV simultaneously	19	2010
	Nested PCR	EBV	18/62 (29%)					
China and Japan	ISH-tyramide	HPV	0/20 (0%)	Tumoral	–	All the 20 cases were well-differentiated	53	2001
	<i>In situ</i> PCR		20/20 (100%)					
China	PCR	HPV	35/38 (92.1%)	Tumoral	HPV-16	–	38	2001
	mRNA-ISH	hTRT	31/35 (88.5%)					
South Africa	ISH-tyramide	HPV	0/59 (0%)	–	HPV-18	–	4	2006
	ISH		0/59 (0%)					
	Real-time PCR		7/59 (11.8%)					
Sudan	Radioactive ISH	HPV	0/66 (0%)	–	–	One case of staining in non-neoplastic epithelium	55	1995
	IHC		0/66 (0%)					
Sudan	PCR	HPV	54/217 (24.8%)	–	–	–	20	2010
	Nested PCR	EBV	69/217 (31.7%)					
Finland	ISH	HPV	1/40 (2.5%)	Tumoral	HPV-6, 16, 18	HPV DNA was not found in specimens from tumor-free margins	7	1990
	PCR		11/40 (27.5%)					
	Radioactive ISH	HPV	6/51 (11.8%)	Tumoral	HPV-16, 18		–	48
Italy	DNA sequencing	HPV	7/64(10.9%)	Tumor cells	HPV-6, 16, 31, 44, 53, 56, 70	–	37	2012
	ISH		2/64(3.1%)					
	ISH-tyramide	HPV	3/11 (27.2%)	Tumoral	–	Just non-smokers and non-drinkers	3	2010
	Nested PCR		3/11 (27.2%)					
IHC	p16	6/11 (54.5%)						
		p53	9/11 (81.8%)					
ISH	HPV	9/15 (60%)	Tumoral	HPV-6/11, 16/18, 31/33/35	Just <i>in situ</i> and early carcinomas	30	1997	

Country	Techniques	Target	Positive cases (em OSCC)	Stained cell type	Genotypes	Observations	Ref.	Year
Spain	ISH	HPV	10/27 (37%)	Tumoral	–	HPV more frequent in well-differentiated tumors	13	1994
Germany	ISH	HPV	7/12 (58.3%)	Tumoral	HPV-6, 11, 16, 18	Just non-smoking and non-drinking patients with T2N0M0 tongue tumors	17	1992
Hungary	PCR IHC	HPV p16 p53 pRb	33/79 (41.7%) 13/79 (16.4%) 45/79 (56.9%) 63/79 (79.7%)	Tumoral	HPV-16	–	33	2006
Czech Republic	ISH-tyramide PCR IHC	HPV p16	6/24 (25%) 3/24 (13%) 7/24 (29%)	Tumoral	HPV-16	Just non-smokers and non-drinkers Lip tumors were not included	25	2011
Netherlands	ISH-tyramide PCR	HPV	0/7 (0%) 0/7 (0%)	–	–	Just non-smokers and non-drinkers with tongue tumors	45	2008
Serbia	PCR dPCR SSCP	HPV c-myc p53	6/60 (10%) 21/60 (35%) 36/60 (60%)	–	HPV16	–	39	2010
USA	PCR IHC	HPV p16 p53	4/26 (15.3%) 15/29 (51.7%) 27/29 (93.1%)	Tumoral	–	–	14	2008
	ISH	HPV	2/36 (5.5%)	Non-neoplastic epithelium	HPV6/11, 16/18	Smoking and drinking patients	1	1991
	ISH PCR	HPV	1/10 (10%) 1/10 (10%)	Tumoral	HPV-16/18	–	44	1991
	ISH	HPV	0/17 (0%)	–	–	–	57	1991
	ISH	HPV	0/20 (0%)	–	–	Five <i>in situ</i> carcinomas were included	58	1991
USA Venezuela	ISH <i>In situ</i> PCR	HPV	0/30 (0%) 20/30 (66.7%)	Tumoral	HPV-16, 18	–	31	1994
Brazil	PCR dot blot IHC	HPV p53 Bcl-2	26/88 (29.5%) 26/43 (60.4%) 17/43 (39.5%)	–	HPV-16, 18	–	35	2009
	ISH-tyramide	HPV	3/10 (30%)	Tumoral	HPV-16/18, 31/33	–	2	2008
	PCR dot blot IHC	HPV pRb p21	11/33 (33.3%) 24/33 (72.7%) 12/33 (36.3%)	–	HPV-16, 18	–	47	2008
	ISH-tyramide	HPV	2/12 (16.6%)	Tumoral	HPV-16/18	HPV-positive cases compatible with <i>in situ</i> carcinoma	46	2002
	Argentina	ISH	HPV	8/33 (24.2%)	Tumoral	–	Five HPV(+) cases were verrucous carcinomas	5

*dPCR*: differential PCR; *EBER1-ISH*: ISH using probes complementary to EBV-encoded RNA 1 (*EBER1*); *EBV*: Epstein-Barr virus; *HPV*: human papillomavirus; *hTERT*: human telomerase reverse transcriptase; *IHC*: immunohistochemistry; *in situ PCR*: PCR followed by ISH, both on slide; *ISH*: conventional *in situ* hybridization; *ISH-AT*: *ISH-AT* Tailing; *ISH-tyramide*: ISH with a biotinyl-tyramide-based signal amplification system; *mRNA-ISH*: ISH with probes directed towards a target messenger ribonucleic acid; *nested PCR*: two sets of primers used in two successive PCR runs, aiming at reducing non-specific amplification; *PCR dot blot*: PCR amplification followed by dot blot hybridization for virus typing; *PCR*: polymerase chain reaction; *qPCR*: quantitative PCR; *radioactive ISH*: ISH using radioactive labelled probes; *Ref.*: reference; *SSCP*: single strand conformation polymorphism.

### Considerations about viral prevalence

According to a meta-analysis carried out by Miller and White<sup>(52)</sup>, in which 58 studies were reviewed, accounting for 1,051

cases of OSCC, the average prevalence of HPV was 26.2%. In a more recent meta-analysis in which 47 studies on OSCC published between 1988 and 2007 were reviewed, the average prevalence

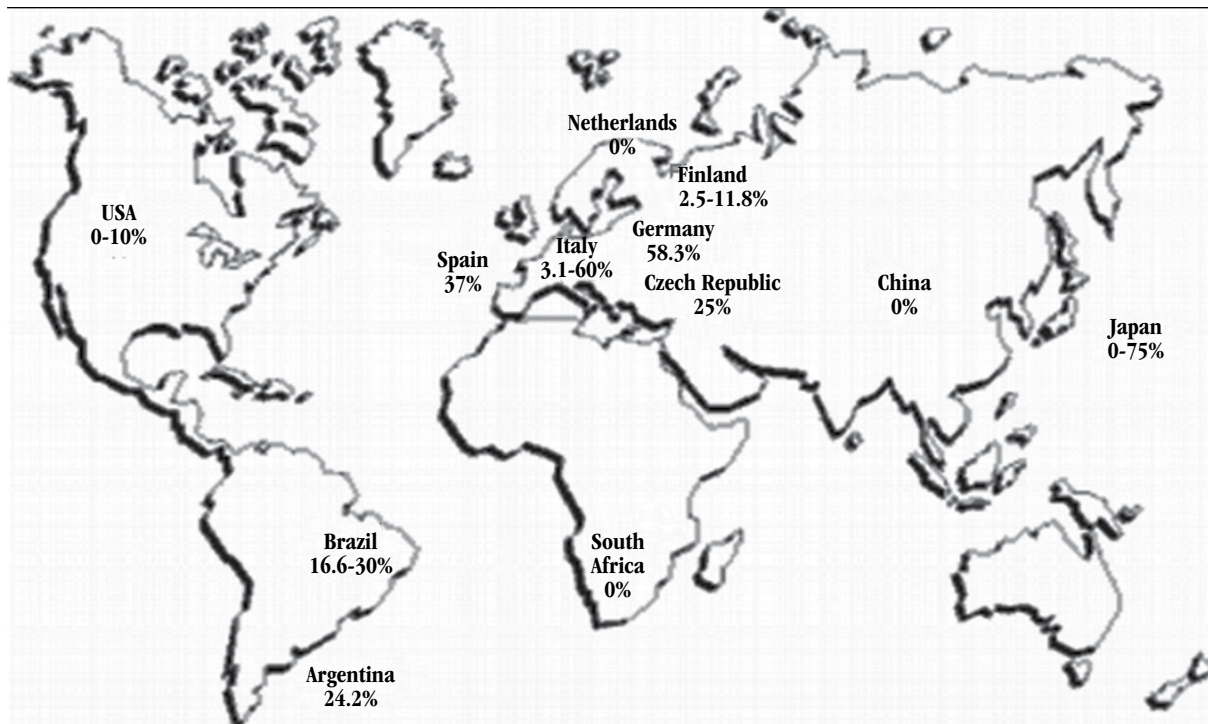


FIGURE – HPV prevalence rates found in studies carried out in different parts of the world using in situ hybridization techniques

was 38.1%<sup>(51)</sup>. In both studies the prevalence rates ranged from 0% to 100%. Such a variation depends on the sensitivity of the employed technique, the sample size, the state of conservation of the clinical specimens, and epidemiological factors of the studied population<sup>(6)</sup>. The first meta-analysis found out that the studies in which carcinoma specimens were collected fresh and kept frozen, and then submitted to PCR technique, presented a prevalence rate of 51.6% (115 out of 223). On the other hand, the researches that used ISH in paraffin-embedded specimens demonstrated a prevalence of 21.7% (136 out of 628)<sup>(32)</sup>. In the study by Termine *et al.*<sup>(51)</sup>, the average prevalence obtained by ISH was 29.8%, whereas by PCR was 39.9%. The **Figure** presents the attained prevalence rates, by ISH methods, in several researches carried out around the world.

### Considerations about oral and oropharyngeal topography

Another factor that influences knowledge about the actual HPV prevalence in oral lesions includes the precise definition of oral and oropharyngeal tumors. From the anatomical point of view, the border between oral cavity and oropharynx is the posterior third of the tongue. However, it is not always so simple to clinically define it, and the result is that some tumors of a site may be included and analyzed in the other<sup>(16)</sup>. Some authors, like

Tsuhako *et al.*<sup>(52)</sup>, have indistinctly considered the cases of oral and oropharyngeal squamous cell carcinomas in their casuistics. This may be the cause of the elevated determined prevalence rates, considering that oropharyngeal carcinomas demonstrate higher prevalence, and the relationship between HPV and carcinogenesis in this anatomic site is well accepted<sup>(37, 50)</sup>.

### Considerations about viral detection

The screening of a limited number of genotypes is another important factor that may lead to false negative results, and consequently, to an underestimate of HPV role in OSCC. A remarkable example is the study by Kojima *et al.*<sup>(23)</sup>, in which ISH-tyramide exposed an elevated prevalence of HPV-38 (35/53 [66%]), a genotype rarely investigated in other studies. Meanwhile, Pannone *et al.*<sup>(37)</sup> detected genotypes 44, 53, and 70, by DNA sequencing following PCR, but were not successful with the ISH method, as the available commercial kits do not include the corresponding probes: they are designed to detect high-risk genotypes associated with anogenital lesions.

The amount of viral copies may vary depending on the differentiation stage of the host cell, reaching the highest levels in differentiated keratinocytes of the most superficial layers, where viruses are in their vegetative phase. About the sensitivity of the employed techniques, ISH is only able to detect HPV when the rate

is higher than 10 copies of viral DNA per cell, being considered of low sensitivity. The methods of moderate sensitivity, like Southern blot, dot blot, and reverse blot hybridization, can detect it from a rate of one viral copy per cell. PCR demonstrates an expressive ratio, able to detect HPV at a rate lower than a copy of viral DNA per cell, being considered of high sensitivity. Immunofluorescence and immunoperoxidase assays are considered of low sensitivity<sup>(32)</sup>.

Some authors affirm that ISH sensitivity could be improved by means of a biotinyl-tyramide-based detection system, amplifying the signal and, thus, allowing the detection even of a single viral copy per infected cell<sup>(9, 28)</sup>. According to Syrjänen *et al.*<sup>(50)</sup>, ISH is perhaps more sensitive than PCR, especially when few cells in the specimen contain viral copies that may not be detected by PCR, depending on the tissue portion used for DNA obtainment, what demonstrates the importance of studies using *in situ* approaches.

It is interesting to note that technical specificity may also influence HPV detection, and consequently, prevalence rates. Still according to the meta-analysis by Miller and White<sup>(32)</sup>, studies involving PCR using primers to detect early HPV genes yielded an average prevalence of 42.7% (88 out of 206), whereas those using primers designed for HPV late regions presented prevalence of 22.5% (48 out of 213). The discrepancy is enlarged as one considers only studies that detected HPV-16/18, with prevalence rates of 46.7% (84 out of 180) for the early region, and 15.9% (33 out of 208) for the late region. Probably, such differences are due to the disruption of the viral genome, most frequently in sites located in the late region, during integration to the host genome. As a result, false negative results may occur when primers are used in the late regions. However, disruption may eventually occur in early regions, with a possible underestimate of prevalence when using primers for this region of viral genome<sup>(16)</sup>.

Although the Southern blot requires a significant amount of DNA for its conduction, it allows defining whether HPV is in the episomal or integrated form. Moreover, it is not prone to contamination errors, an event that may occur with PCR and is difficult to control, because PCR is very sensitive, besides offering simply a binary finding. Thus, techniques as the Southern blot and quantitative PCR (qPCR) provide means for quantification to differentiate low-level positivity from contamination<sup>(16)</sup>.

### **Controversy about the role of HPV in the oral carcinoma**

Although the presence of HPV in a percentage of oral carcinomas has been confirmed, as previously exposed, viral detection only does not prove the causal relationship between this agent and the aforementioned neoplasia. These results, from

studies of diverse designs, allow inferring the possibility of the cited virus participation in oral carcinogenesis, but direct experimental evidence establishing cause and effect is required for confirmation. For Feller *et al.*<sup>(10)</sup>, it is necessary that a significant number of individuals harboring HPV in the oral mucosa develop carcinoma in a certain period, as can be seen in cases of squamous carcinoma of the uterine cervix. The presence of high-risk genotypes with confirmed expression of E6 and E7 oncoproteins in the malignant cells, both in the primary site and in metastases, and viral monoclonality are also decisive.

The existence of a substantial number of viral DNA copies (viral load) in the neoplastic tissue also provokes an involvement of the microbial agent. However, evidence warns that this finding is not a reliable prediction of HPV-induced neoplastic progression, as the determination of viral load does not distinguish between an infection of many cells containing few copies of viral DNA per cell and an infection of few cells with a large number of viral copies per cell, or even between long-standing infection and recent infection<sup>(10)</sup>.

Although the mucosae of the oral cavity and uterine cervix share histologic similarities, significant differences are observed as to neoplastic development. The oral mucosa, for example, is more exposed to a series of carcinogens such as alcohol, tobacco and betel, which play an important role in the etiology of oral neoplasms. In the uterine cervix, HPV seems to be the main triggering factor, with more than 90% of association. Regarding HPV in squamous oral carcinomas, other differences have been observed, among which, the infrequent viral integration and isolation of genotypes 31, 33, and 35, commonly observed in cervical carcinomas, as well as the relatively lower overall prevalence in oral carcinomas. These examples illustrate the differences in mechanisms of oncogenesis between both sites; it is possible, then, that HPV presents a distinct behavior in the oral mucosa, and still plays a role in the neoplastic process<sup>(10, 32)</sup>.

Concerning viral integration into the host genome, although it is a strong indicator of the viral oncogenic role, the presence of high viral load followed by the high-risk E6 and E7 mRNA active expression may occur, for instance, in malignant cells of squamous carcinoma of the oropharynx in the episomal form<sup>(6)</sup>.

Other aspects that hinder define the role of HPV in oral carcinogenesis include its identification in samples of normal mucosa, benign leukoplakia and intraepithelial neoplasia, with significant prevalence rates of 13.5%, 14.8%, and 27%, respectively, according to a meta-analysis carried out by Miller and White<sup>(32)</sup>. Even more intriguing is the detection of high-risk genotypes in the mentioned samples, besides the scarcity of cases of oral carcinoma

for which HPV is the only known risk factor, that is, without including tobacco use and/or alcohol consumption, what would provide a more accurate analysis of the isolated viral action. In general, this group of patients, when observed, represents a small part, around 7.3% of the studied samples<sup>(32)</sup>. The limited number of studies assessing the expression of viral oncoproteins and their effects on oral lesions also makes it difficult to understand viral behavior *in situ*.

Castro and Bussoloti Filho<sup>(6)</sup> highlight also the fact that the virus is detected just in a subset of tumor cells when cell localization techniques are used, usually with low viral load. Both findings, added to the presence of HPV in samples of normal oral mucosa and pre-neoplastic lesions, may suggest that this virus is merely a passenger in the oral cavity. On the other hand, we cannot exclude the possibility of a progressive loss of viral genome copies after the establishment of neoplasia, a mechanism named “hit and run”. Thus, HPV would play an important role in tumor development that could be underestimated due to the loss of viral copies during the process, with the resulting failure of the detection techniques<sup>(10, 32)</sup>.

Another intriguing finding is the relatively favorable prognosis of HPV-associated oral carcinomas. In this context, the meta-analysis conducted by O’Rorke *et al.*<sup>(36)</sup> concluded that not only OSCC cases, but head and neck carcinomas in general exhibited better survival in relation to HPV-negative cases. It is admitted that HPV-positive tumors commonly present the wild-type *TP53* gene, whereas cases not related to HPV harbor mutations in the referred gene which, in their turn, are associated with worse prognosis. That would help explain the prognostic profiles verified among HPV-positive and HPV-negative cases<sup>(26)</sup>.

### Evidence confirming the role of HPV

The findings that confirm HPV participation in the development of oral squamous carcinomas include the predominant detection of high-risk genotypes (HPV-16/18), the increased prevalence of HPV in dysplasia and squamous carcinomas compared with the normal mucosa, mainly as to high-risk genotypes, indicating HPV as an independent risk factor for the mentioned neoplastic type<sup>(6, 21, 50)</sup>. Correspondence around 76% has been found between genotypes identified in tumor sites and metastatic lymph nodes<sup>(32)</sup>. Lind *et al.*<sup>(27)</sup> reported that seven of 13 cases of HPV-positive leukoplakias progressed to oral carcinoma within a 10-year period, but genotypes were not reported. Nonetheless, studies show that oral human keratinocytes expressing E6 and E7 genes from HPV-16 become immortal, as previously demonstrated in other keratinocyte cell lines<sup>(54)</sup>.

We must remember there is no certainty as to the necessity of viral integration, in the oral cavity, for the activation of viral oncogenesis<sup>(16)</sup>. HPV isolation, however, especially high-risk, in non-tumoral oral mucosa may be related to the latency period of the virus in the tissue. Subclinical infections of the oral and oropharyngeal mucosae by HPV are common. It is possible that these sites function as reservoirs where viruses remain quiescent, and later, when activated, may play a role in the development of local carcinomas<sup>(10)</sup>. Besides, viral presence does not necessarily indicate active viral expression, as demonstrated in studies with cases of HPV-positive head and neck squamous carcinoma, in which less than half of the cases (9 out of 20) showed E6 mRNA expression<sup>(54)</sup>.

Miller and White<sup>(32)</sup>, based on the body of evidence observed until then, ascertain that HPV involvement in the neoplastic process is clear, and warn that possibly some genotypes still have not been identified in oral lesions, what would explain the relatively low prevalence. If HPV were transient, at least one of the following characteristics should be verified: 1. similar prevalence of HPV among samples of tumor, normal mucosa and pre-neoplastic lesions, including non-tumoral specimens obtained from sites far from the lesions in patients affected by squamous carcinoma; 2. viral prevalence differences in biopsy samples and in oral squamous carcinoma cell lines, due to the potential selectivity of HPV-negative cells during culture; 3. indifferent prevalence of high- and low-risk genotypes in oral cancer samples. Such characteristics were not verified in retrospective analyses, though.

As stated by Syrjänen *et al.*<sup>(50)</sup> when considering the modified Koch’s postulates, at least three conditions necessary to formally confirm the role of HPV as an etiological agent of OSCC have already been satisfied: 1. presence of viral genome in tumor lesions or tumor cells; 2. ability of the virus or viral protein to transform cells *in vitro*; 3. ability of the virus or viral protein to promote tumor formation in animals. As to the other criteria: 4. viral infection precedes cancer development – in spite of the few prospective studies, we must not forget the work by Lind *et al.*<sup>(27)</sup>, in which some cases of infected leukoplakia progressed to carcinoma within a 10-year period; 5. epidemiologic association between presence of the virus and development of cancer – although the association has not been proved, several works demonstrate that the prevalence of HPV is higher in pre-neoplastic lesions and carcinomas when compared with the normal mucosa<sup>(21, 50)</sup>; and finally, 6. prophylactic HPV vaccination would eliminate OSCC – this effect will only be correctly assessed years after implementation of a vaccine program.

## CONCLUSIONS

Although there still is a certain skepticism about the association of HPV and OSCC, it is important to remember examples like that of *Helicobacter pylori* and HPV itself: time, technological advances and successive studies have been able to confirm their participations in the development of, respectively, gastric and cervical carcinomas, many years after the first suggestion. The relationship between HPV and oral carcinomas have been investigated for three decades, and as previously stated, in spite of the conflicting findings, there is a mass of evidence confirming the involvement of this virus in a percentage OSCC, which may reach a little more than a quarter of OSCC. Another interesting aspect is the distinct pattern of infections in these oral tumors, including the participation of uncommon genotypes in

cervical malignant lesions, such as HPV-38, 44, 53, and 70, which may be underestimated, as the available kits for the detection of HPV are based on genotypes considered of high risk for anogenital lesions. Equally interesting is the possibility of carcinogenic action without the occurrence of viral integration, verified by the high E6 and E7 mRNA expression, of high-risk genotypes, in whose cases the virus was in its episomal form. All these pieces of evidence reinforce the thesis of HPV participation in the genesis of oral carcinomas, while warn about the possible unexpected viral behaviors that, sometimes, are not noticed or understood due to the technological limitation of the time and the shortage of studies with the adequate approach. From now on, it is fundamental to develop appropriate research designs, with emphasis on case-control studies that may bring more consistent information about the cause-effect relationship between HPV and OSCC.

## RESUMO

*O papilomavírus humano (HPV) é um agente epiteliotrópico cujos genótipos de alto risco têm uma ligação já bem estabelecida com o desenvolvimento de cânceres cervicais. Embora a relação do HPV com o carcinoma de células escamosas oral (CCEO) venha sendo estudada desde o início da década de 1980, seu papel na carcinogênese oral e os prováveis mecanismos moleculares subjacentes ainda não estão completamente elucidados. Realizou-se uma revisão sistemática dos trabalhos existentes na literatura científica internacional até o momento da elaboração deste manuscrito concernente à associação do HPV com o CCEO, esquadrinhando as características das amostras, das prevalências verificadas, das técnicas utilizadas e os achados relevantes dos estudos. Os resultados demonstram que o HPV está associado a cerca de um quarto dos CCEO. Outro aspecto interessante refere-se ao padrão distinto das infecções nesses tumores orais, incluindo a participação de genótipos incomuns em lesões malignas cervicais, tais como HPV-38, 44, 53 e 70. Igualmente interessante é a possibilidade de atuação carcinogênica sem a ocorrência de integração viral, constatada pela elevada expressão de ácido ribonucleico mensageiro (RNAm) de E6 e E7, de genótipos de alto risco, em casos cujo vírus encontrava-se em estado episomal. Essas evidências reforçam a tese do envolvimento do HPV na gênese dos CCEO, ao mesmo tempo em que alertam para a possibilidade de comportamentos virais inesperados que, por vezes, não são percebidos ou compreendidos devido à limitação tecnológica da época e à carência de estudos com abordagem apropriada.*

*Unitermos:* HPV; câncer oral; carcinoma de células escamosas.

## REFERENCES

1. ABDELSAYED, R. Study of human papillomavirus in oral epithelial dysplasia and epidermoid carcinoma in the absence of tobacco and alcohol use. *Oral Surg Oral Med Oral Pathol*, v. 71, n. 6, p. 730-2, 1991.
2. ACAY, R.; *et al.* Human papillomavirus as a risk factor in oral carcinogenesis: a study using in situ hybridization with signal amplification. *Oral Microbiol Immunol*, v. 23, n. 4, p. 271-4, 2008.
3. ANGIERO, F. *et al.* Frequency and role of HPV in the progression of epithelial dysplasia to oral cancer. *Anticancer Res*, v. 30, n. 9, p. 3435-40, 2010.
4. BOY, S.; *et al.* HPV detection in primary intra-oral squamous cell carcinomas – commensal, aetiological agent or contamination? *J Oral Patbol Med*, v. 35, n. 2, p. 86-90, 2006.
5. BUSTOS, D. A. *et al.* Human papillomavirus detection in oral cancer lesions in the city of Córdoba. *Rev Fac Cien Med Univ Nac Cordoba*, v. 56, n. 1, p. 65-71, 1999.
6. CASTRO, T. P. P. G.; BUSSOLOTTI FILHO, I. Prevalência do papilomavírus humano (HPV) na cavidade oral e na orofaringe. *Rev Bras Otorrinolaringol*, v. 72, n. 2, p. 272-82, 2006.
7. CHANG, F. *et al.* Detection of human papillomavirus (HPV) DNA in oral squamous cell carcinomas by *in situ* hybridization and polymerase chain reaction. *Arch Dermatol Res*, v. 282, n. 8, p. 493-7, 1990.



8. CHEN, P. C. *et al.* Risk of oral cancer associated with human papillomavirus infection, betel quid chewing, and cigarette smoking in Taiwan – an integrated molecular and epidemiological study of 58 cases. *J Oral Pathol Med*, v. 31, n. 6, p. 317-22, 2002.
9. EVANS, M. F.; ALIESKY, H. A.; COOPER, K. Optimization of biotinyl-tyramide-based in situ hybridization for sensitive background-free applications on formalin-fixed, paraffin-embedded tissue specimens. *BMC Clin Pathol*, v. 3, n. 2, p. 1-17, 2003.
10. FELLER, L. *et al.* Human papillomavirus-mediated carcinogenesis and HPV-associated oral and oropharyngeal squamous cell carcinoma. Part 2: Human papillomavirus associated oral and oropharyngeal squamous cell carcinoma. *Head Face Med*, v. 6, n. 15, p. 1-6, 2010.
11. FUJITA, S.; *et al.* Human papillomavirus infection in oral verrucous carcinoma: genotyping analysis and inverse correlation with p53 expression. *Pathobiology*, v. 75, n. 4, p. 257-64, 2008.
12. GARCÍA-TAMAYO, J.; MOLINA, J.; BLASCO-OLAETXEA, E. El virus del papiloma humano y el cáncer cervical. Una revisión de la historia actualizada sobre la investigación del cáncer del cuello uterino en Venezuela. *Invest Clin*, v. 51, n. 2, p. 193-208, 2010.
13. GONZALEZ-MOLES, M. A. *et al.* Detection of HPV DNA by in situ hybridization in benign, premalignant and malignant lesions of the oral mucosa. *Bull Group Int Rech Sci Stomatol Odontol*, v. 37, n. 3-4, p. 79-85, 1994.
14. GREER, R. O. *et al.* Is p16INK4a protein expression in oral ST lesions a reliable precancerous marker? *Int J Oral Maxillofac Surg*, v. 37, p. 840-6, 2008.
15. GREER, R. O.; EVERSOLE, L. R.; CROSBY, L. K. Detection of human papillomavirus-genomic DNA in oral epithelial dysplasias, oral smokeless tobacco-associated leukoplakias, and epithelial malignancies. *J Oral Maxillofac Surg*, v. 48, n. 11, p. 1201-5, 1990.
16. HA, P. K.; CALIFANO, J. A. The role of human papillomavirus in oral carcinogenesis. *Crit Rev Oral Biol Med*, v. 15, n. 4, p. 188-96, 2004.
17. HÖNIG, J. F. Non radioactive in situ hybridization for detection of human papilloma virus DNA in squamous cell carcinoma of tongue. *Bull Group Int Rech Sci Stomatol Odontol*, v. 35, n. 3-4, p. 107-15, 1992.
18. ISHIBASHI, M. *et al.* The prevalence of human papillomavirus in oral premalignant lesions and squamous cell carcinoma in comparison to cervical lesions used as a positive control. *Int J Clin Oncol*, v. 16, n. 6, p. 646-53, 2011.
19. JALOULI, J. *et al.* Prevalence of viral (HPV, EBV, HSV) infections in oral submucous fibrosis and oral cancer from India. *Acta Otolaryngol*, v. 130, n. 11, p. 1306-11, 2010a.
20. JALOULI, J. *et al.* Presence of human papilloma virus, herpes simplex virus and Epstein-Barr virus DNA in oral biopsies from Sudanese patients with regard to toombak use. *J. Oral Pathol Med*, v. 39, n. 8, p. 599-604, 2010b.
21. JAYAPRAKASH, V. *et al.* Human papillomavirus types 16 and 18 in epithelial dysplasia of oral cavity and oropharynx: a meta-analysis, 1985-2010. *Oral Oncol*, v. 47, n. 11, p. 1048-54, 2011.
22. JEMAL, A. *et al.* Global cancer statistics. *CA Cancer J Clin*, v. 61, n. 2, p. 69-90, 2011.
23. KOJIMA, A. *et al.* Human papillomavirus type 38 infection in oral squamous cell carcinomas. *Oral Oncol*, v. 38, n. 6, p. 591-6, 2002.
24. KOYAMA, K.; UOBE, K.; TANAKA, A. Highly sensitive detection of HPV-DNA in paraffin sections of human oral carcinomas. *J. Oral Pathol Med*, v. 36, n. 1, p. 18-24, 2007.
25. LACO, J. *et al.* The role of high-risk human papillomavirus infection in oral and oropharyngeal squamous cell carcinoma in non-smoking and non-drinking patients: a clinicopathological and molecular study of 46 cases. *Virchows Arch*, v. 458, n. 2, p. 179-87, 2011.
26. LEEMANS, C. R.; BRAAKHUIS, B. J.; BRAKENHOFF, R. H. The molecular biology of head and neck cancer. *Nat Rev Cancer*, v. 11, n. 1, p. 9-22, 2011.
27. LIND, P. O. *et al.* Local immunoreactivity and human papillomavirus (HPV) in oral precancer and cancer lesions. *Scand J Dent Res*, v. 94, n. 5, p. 419-26, 1986.
28. LIZARD, G. *et al.* In situ hybridization detection of single-copy human papillomavirus on isolated cells, using a catalyzed signal amplification system: GenPoint. *Diagn Cytopathol*, v. 24, n. 2, p. 112-6, 2001.
29. LONING, T. *et al.* Analysis of oral papillomas, leukoplakias, and invasive carcinomas for human papillomavirus type related DNA. *J Invest Dermatol*, v. 84, n. 5, p. 417-20, 1985.
30. MIGNOGNA, M. D. *et al.* The presence of human papillomavirus (HPV) in microinvasive in situ spinocellular carcinoma of the oral cavity. Preliminary report. *Minerva Stomatol*, v. 46, n. 6, p. 287-91, 1997.
31. MILLER, C. S. *et al.* Detection of HPV DNA in oral carcinoma using polymerase chain reaction together with in situ hybridization. *Oral Surg Oral Med Oral Pathol*, v. 77, n. 5, p. 480-6, 1994.
32. MILLER, C. S.; WHITE, D. K. Human papillomavirus expression in oral mucosa, premalignant conditions, and squamous cell carcinoma: a retrospective review of the literature. *Oral Surg Oral Med Oral Pathol Oral Radiol Endod*, v. 82, n. 1, p. 57-68, 1996.
33. NEMES, J. A. *et al.* Expression of p16INK4A, p53, and Rb proteins are independent from the presence of human papillomavirus genes in oral squamous cell carcinoma. *Oral Surg Oral Med Oral Pathol Oral Radiol Endod*, v. 102, n. 3, p. 344-52, 2006.
34. ODA, D. *et al.* HPV immortalization of human oral epithelial cells: a model for carcinogenesis. *Exp Cell Res*, v. 226, n. 1, p. 164-9, 1996.
35. OLIVEIRA, M. C. *et al.* High-risk human papillomavirus (HPV) is not associated with p53 and bcl-2 expression in oral squamous cell carcinomas. *Auris Nasus Larynx*, v. 36, p. 450-6, 2009.
36. O'RORKE, M. A. *et al.* Human papillomavirus related head and neck cancer survival: a systematic review and meta-analysis. *Oral Oncol*, v. 48, n. 12, p. 1191-201, 2012.
37. PANNONE, G. *et al.* Evaluation of a combined triple method to detect causative HPV in oral and oropharyngeal squamous cell carcinomas: p16 immunohistochemistry, Consensus PCR HPV-DNA, and *in situ* hybridization. *Infect Agent Cancer*, v. 7, n. 4, 2012.
38. PATIMAN; ZHANG, Z.; CAO, J. Research on expression of human papillomavirus type 16 and telomerase in oral lesions. *Zhonghua Kou Qiang Yi Xue Za Zhi*, v. 36, n. 2, p. 119-21, 2001.
39. POPOVI, B. *et al.* Cancer genes alterations and HPV infection in oral squamous cell carcinoma. *Int J Oral Maxillofac Surg*, v. 39, n. 9, p. 909-15, 2010.
40. RIVERO, E. R. C.; NUNES, F. D. HPV in oral squamous cell carcinomas of a Brazilian population: amplification by PCR. *Braz Oral Res*, v. 20, n. 1, p. 21-4, 2006.

41. ROSEBUSH, M. S. *et al.* Oral cancer: enduring characteristics and emerging trends. *J Tenn Dent Assoc*, v. 91, n. 2, p.24-7, 2011.
42. SHIMIZU, M. *et al.* Detection of various types of human papillomavirus DNA, mainly belonging to the cutaneous-group, more frequently in normal tissue than in squamous cell carcinomas of the lip. *J Dermatol Sci*, v. 36, n. 1, p. 33-9, 2004.
43. SHINDOH, M. *et al.* Detection of human papillomavirus DNA sequences in oral squamous cell carcinomas and their relation to p53 and proliferating cell nuclear antigen expression. *Cancer*, v. 76, n. 9, p. 1513-21, 1995.
44. SHROYER, K. R.; GREER, R. O. Detection of human papillomavirus DNA by in situ DNA hybridization and polymerase chain reaction in premalignant and malignant oral lesions. *Oral Surg Oral Med Oral Pathol*, v. 71, n. 6, p. 708-13, 1991.
45. SIEBERS, T. J. H. *et al.* No high-risk HPV detected in SCC of the oral tongue in the absolute absence of tobacco and alcohol – a case study of seven patients. *Oral Maxillofac Surg*, v. 12, n. 4, p. 185-8, 2008.
46. SOARES, C. P. *et al.* Presença do papilomavírus humano em lesões malignas de mucosa oral. *Rev Soc Bras Med Trop*, v. 35, n. 5, p. 439-44, 2002.
47. SOARES, R. C. *et al.* Detection of HPV DNA and immunohistochemical expression of cell cycle proteins in oral carcinoma in a population of Brazilian patients. *J Appl Oral Sci*, v. 16, n. 5, p. 340-4, 2008.
48. SYRJÄNEN, S. M.; SYRJÄNEN, K. J.; HAPONEN, R. Human papillomavirus (HPV) DNA sequences in oral precancerous lesions and squamous cell carcinoma demonstrated by in situ hybridization. *J Oral Pathol*, v. 17, n. 6, p. 273-8, 1988.
49. SYRJÄNEN, K. *et al.* Morphological and immunohistochemical evidence suggesting human papillomavirus (HPV) involvement in oral squamous cell carcinogenesis. *Int J Oral Surg*, v. 12, n. 6, p. 418-24, 1983.
50. SYRJÄNEN, S. *et al.* Human papillomaviruses in oral carcinoma and oral potentially malignant disorders: a systematic review. *Oral Dis*, v. 17, suppl. 1, p. 58-72, 2011.
51. TERMINE, N. *et al.* HPV in oral squamous cell carcinoma vs. head and neck squamous cell carcinoma biopsies: a meta-analysis (1988-2007). *Ann Oncol*, v. 19, n. 10, p. 1681-90, 2008.
52. TSUHAKO, K. *et al.* Comparative study of oral squamous cell carcinoma in Okinawa, Southern Japan and Sapporo in Hokkaido, Northern Japan; with special reference to human papillomavirus and Epstein-Barr virus infection. *J Oral Pathol Med*, v. 29, n. 2, p. 70-9, 2000.
53. UOBE, K. *et al.* Detection of HPV in Japanese and Chinese oral carcinomas by in situ PCR. *Oral Oncol*, v. 37, n. 2, p. 146-52, 2001.
54. VAN HOUTEN, V. M. *et al.* Biological evidence that human papillomaviruses are etiologically involved in a subgroup of head and neck squamous cell carcinomas. *Int J Cancer*, v. 93, n. 2, p. 232-5, 2001.
55. VAN RENSBURG, E. J. *et al.* Detection of EBV DNA in oral squamous cell carcinomas in a black African population sample. *In Vivo*, v. 9, n. 3, p. 199-202, 1995.
56. WEINBERGER, P. M. *et al.* Molecular classification identifies a subset of human papillomavirus-associated oropharyngeal cancers with favourable prognosis. *J Clin Oncol*, v. 24, n. 5, p. 736-47, 2006.
57. YOUNG, S. K.; MIN, K. W. In situ DNA hybridization analysis of oral papillomas, leukoplakias, and carcinomas for human papillomavirus. *Oral Surg Oral Med Oral Pathol*, v. 71, n. 6, p. 726-9, 1991.
58. ZEUSS, M. S. *et al.* In situ hybridization analysis of human papillomavirus DNA in oral mucosal lesions. *Oral Surg Oral Med Oral Pathol*, v. 71, n. 6, p. 714-20, 1991.

---

**MAILING ADDRESS**

Marcos Antonio Pereira de Lima

Universidade Federal do Ceará – Faculdade de Medicina do Cariri; Rua Divino Salvador, 284 – Rosário; CEP: 63180-000, Barbalha-CE, Brazil; e-mail: marcosantonio@ufc.br.