

# Forensic dental examinations carried out in a large city in northeastern Brazil

*Perícias criminais odontológicas realizadas em um município de grande porte do nordeste brasileiro*

Raquel Oliveira BANDEIRA<sup>1</sup>  
Léa Maria Bezerra de MENEZES<sup>1</sup>  
Patrícia Maria Costa de OLIVEIRA<sup>1</sup>  
Adriana de Moraes CORREIA<sup>2</sup>

## ABSTRACT

### Objective

The objective of the present study is to analyze all of the forensic dental examinations carried out by the Forensic Investigation Division of the State of Ceará, in Fortaleza, in 2009, and their objectives, bearing in mind that forensic dentistry consists of all the procedures that aim to provide clarification to the Courts of Law with the objective of filling the gaps in specific knowledge by the pertinent authorities in the most diverse areas of human knowledge and in addition, that these criminal investigations can be performed by dental surgeons in accordance with Article 6 of Law 5,081 of August 24, 1966, which regulates the practice of Dentistry in Brazil.

### Methods

The study was document-based with an observational and descriptive outline having been carried out using data collected based on the analysis of the case records of the subjects examined, made available in spreadsheet format by the Information Technology Office at the Ceará State Forensic Investigation Department, concealing data that might enable the identification of the subjects under examination.

### Results

In accordance with the information supplied by the institution, 600 exams were carried out in 2009 in the Forensic Dentistry Center, distributed as follows: 268 (44.67%) age verification examinations, 23 (3.83%) identification examinations and 309 (51.5%) diagnostic investigations of bodily injury.

### Conclusion

The study vies to publicize the activity of the forensic dentist, reinforcing his/her indispensability in those agencies designed to carry out Criminal investigations.

**Indexing terms:** Expert testimony. Forensic anthropology. Forensic dentistry. Jurisprudence. Legislation.

## RESUMO

### Objetivo

Analisar a totalidade de perícias odontológicas realizadas pela Perícia Forense do Estado do Ceará, em Fortaleza, no ano de 2009, e o objetivo das mesmas, considerando que a perícia odontológica consta de todos os procedimentos que visam fornecer esclarecimentos à Justiça com o objetivo de suprir a insuficiência de conhecimentos específicos pelas autoridades competentes na mais diversas áreas do conhecimento humano. E ainda, que tais perícias podem ser realizadas pelo cirurgião-dentista conforme o Artigo 6º da Lei n. 5.081, de 24 de agosto de 1966, que regula o exercício da Odontologia no Brasil.

### Métodos

O estudo se caracterizou como documental com um delineamento observacional e descritivo, tendo sido realizado através de dados coletados com base em análises dos prontuários de periciandos, disponibilizados em planilhas pela Coordenadoria de Tecnologia da Informação da Perícia Forense do Estado do Ceará, resguardando dados que pudessem identificar os periciandos.

### Resultados

De acordo com as informações fornecidas pela instituição, no ano supracitado foram realizadas 600 perícias no Núcleo de Odontologia Forense, estando assim distribuídas: 268 (44,67%) exames de verificação de idade, 23 (3,83%) perícias de identificação e 309 (51,50%) diagnósticos de lesão corporal.

### Conclusão

O estudo concorre para a divulgação da atuação do Odontolegista, reforçando a imprescindibilidade deste profissional nos órgãos destinados a realização de Perícias.

**Termos de indexação:** Prova pericial. Antropologia forense. Odontologia legal. Jurisprudência. Legislação.

<sup>1</sup> Universidade Federal do Ceará, Faculdade de Farmácia, Odontologia e Enfermagem, Departamento de Clínica Odontológica. Rua Monsenhor Furtado, s/n., Rodolfo Teófilo, 60430-350, Fortaleza, CE, Brasil. Correspondência para / Correspondence to: LMB MENEZES. E-mail: <lbezerrademenezes@yahoo.com.br>.

<sup>2</sup> Perícia Forense do Estado do Ceará, Núcleo de Odontologia Legal. Fortaleza, CE, Brasil.

## INTRODUCTION

The reality of what is crime in our society is very complex and it often compels the judiciary to turn to the assistance of experts to clarify the various cases. These professionals are specialists in specific areas, owners of technical and scientific skills, who perform expert investigations with the aim of preparing legal documents that are the technical proof substantiating equitable rulings in the courts of law<sup>1-4</sup>

The expert is recommended by the Judge who appoints him/her as one of the official experts, as those who exercise this occupation at the behest of public office are designated. There also exist what are known as non-official experts, commended or appointed, assigned to stand in in the absence of official experts, all of whom are specialists in a particular topic<sup>2,5</sup>.

Many professions are capable of offering support of this kind and with this aim, dentistry may help to clarify dental facts of legal interest<sup>2,6</sup>.

The dental specialty responsible for this area of work is called forensic dentistry, which carries out research into psychic, physical, chemical and biological phenomena that may affect or have affected the individual, whether alive, deceased or a pile of bones, and even fragments or traces, resulting in partial or total lesions, whether reversible or not<sup>7</sup>. Professionals working in this area apply their dental skills ranging from the most straightforward to the most complex, in the interests of the Law<sup>1</sup>.

The skill sets of the forensic dentistry specialist include human identification, investigation, evaluation and planning with the study of accidents, forensic thanatology, case document preparation, official reports, opinions, summaries and certificates, dental traumatology for forensic purposes, forensic ballistics, logistics expertise on the living and the deceased, whether intact or dismembered, fragments, expertise with interrelated clues including stains or liquids emanating from or present in the oral cavity, imaging examinations for the purposes of criminal investigation, dental deontology, forensic dental instruction for professional practice and imaging examinations for forensic dental purposes<sup>7</sup>.

The performance of this specialty is limited to events related to the region of the head and neck but may, if circumstances so require, be extended to other areas, if the quest for the truth depends on it, in the strict interests of justice and administration<sup>6</sup>.

As specified in Law 5081 of 1966, which regulates professional practice in Dentistry, one of the responsibilities

of the dental surgeon is that of dental investigation of a forensic nature, which may take place in Civil, Criminal or Labor courts or in administrative proceedings<sup>1-2,4,8</sup>.

Criminal investigations in the area of Dentistry must be performed by Dental Surgeons empowered as forensic experts, attached to the bodies designed to carry out these procedures, commonly known as the Institute of Forensic Medicine or Institute of Medical Jurisprudence<sup>9</sup>.

These investigations consist of examinations which are based on forensic science to analyze material evidence generated through an alleged crime, with the aim of finding out the instruments used, the perpetrator(s), the mechanics and the outcome of the incident in order to provide evidence for the initial legal procedures and through to trial<sup>10</sup>.

In criminal investigations, Forensic Dentistry is important to a number of areas: diagnostic and therapeutic examinations to compare previous dental history of the individual concerned; evaluation of damage to the maxilla, mandibular, teeth and soft oral tissue; identification of individuals found in criminal investigations and/or in mass disasters; identification, examination and evaluation of bite marks that frequently appear in cases of sexual assault, child abuse and in situations of self-defense<sup>5</sup>, as well as the performance of examinations that enable the age of the individuals to be estimated, when not already known, and to assess the level of alcoholic intoxication when appropriate.

In Fortaleza, forensic dental investigations are carried out by dental surgeons within the Ceará State Forensic Investigation Division known as PEFOCE.

As far as the general public is concerned, the role of the forensic dentist in the Institutes of Forensic Medicine and the like is still not widely understood, and even within the profession itself, which generates a lack of due recognition for the professionals exercising this activity.

In many locations, the institutions designed to perform expert investigations do not have a dental surgeon on their team, the dental examinations often being carried out by professionals who do not have the appropriate knowledge to carry them out and, for this reason, they make mistakes when addressing issues in the expert reports or in the processes of human identification.

The aim of this study, therefore, is to get to know and to publicize the types of forensic dental investigations carried out in the Ceará State Forensic Investigation Department, thereby underlining the importance of Forensic Dentistry and the need for dental surgeons to be employed by these institutions.

## METHODS

The research study was performed at the Dental Unit of the Ceará State Forensic Investigation Division in Fortaleza. This institution boasts a team of 16 duty dental surgeons. During the week, there are two dentists on duty for 12 hours during the day and one for 12 hours at night, and on Saturdays and Sundays the forensic experts organize a system of rotation to make up their standard working hours.

Examinations of living subjects are performed in a special room where there is a dental chair, spot lamp, auxiliary unit, a support bench for the examination instruments, a periapical x-ray machine and a computer for inputting documents. Post-mortem examinations are performed at the mortuary.

The study was document-based with an observational and descriptive outline having been carried out using data collected based on the analysis of the case records of the subjects examined, made available in spreadsheet format by the Information Technology Office at the Ceará State Forensic Investigation Department. Identities, and any other data that might enable the identification of the subjects under examination, were concealed. The collection of the information took place during July and August 2010 and the analysis and preparation of the results were performed in the September of the same year.

The data were catalogued, analyzed and discussed, evidencing the types of investigation that occurred most frequently during this period. A descriptive analysis of the results was performed, and they were arranged in the form of pie charts, using Microsoft Excel.

The research Project was approved by the Ethics in Research Committee at the Federal University of Ceará, Record 24/10, Memo 143/10, being within the norms that regulate research on human beings, in accordance with Brazilian Ministry of Health resolution 196/96.

Included in the study were data taken from case records related to investigations that took place in 2009, in the Forensic Dentistry sector, which had been properly completed and were filed in the Files and Records Control Center (NUCEX).

## RESULTS

An analysis of the data revealed that during 2009, a total of 600 investigations were carried out at Fortaleza's

Forensic Dentistry Center at the Ceará State Forensic Investigation Division. Of these, 309 (51.5%) dealt with examinations related to bodily injury while a further 268 (44.67%) corresponded to age estimation examinations and 23 (3.83%) comprised investigations into post-mortem human identification, as shown in Figure 1.

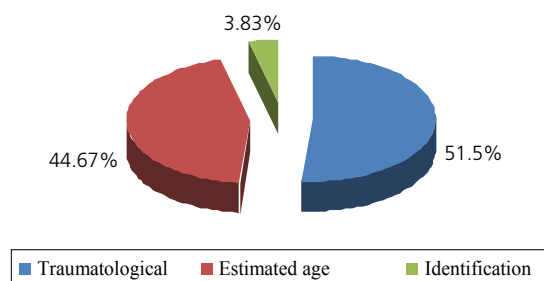


Figure 1. Percentage of investigations carried out in the Forensic Dentistry Center at the Ceará State Forensic Investigation Division. Fortaleza (Ceará), 2009.

As far as identification investigations are concerned, Figure 2 shows that, of the 23 investigations carried out, 78.26% were examinations of corpses and 21.74% were examinations of bone remains.

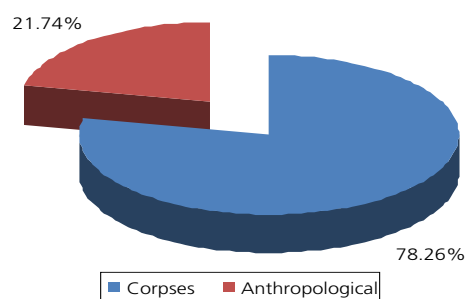
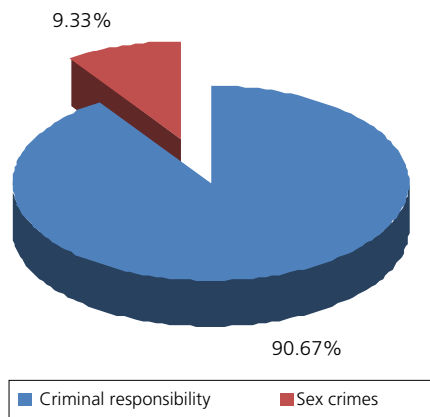


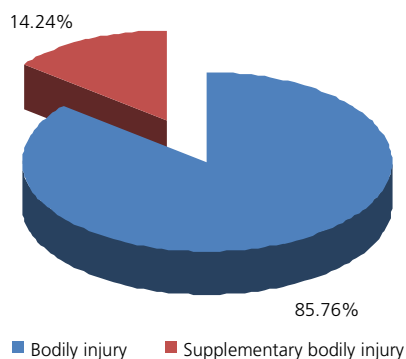
Figure 2. Percentage of Identification Investigations carried out at the Forensic Dentistry Center at the Ceará State Forensic Investigation Division. Fortaleza (Ceará), 2009.

Age estimation investigations were performed with two goals: criminal responsibility and sexually motivated crimes. To check for criminal responsibility, that is to say, to establish the legal capacity of the offender to assume responsibility for the act committed and serve the penalty imposed in accordance with the case, a total of 243 (90.67%) examinations were carried out, while to check the age of the victims of sexually motivated crimes, 25 (9.33%) were carried out. Figure 3 illustrates these data.



**Figure 3.** Percentage of age estimation investigations conducted at the Forensic Dentistry Center at the Ceará State Forensic Investigation Division. Fortaleza (Ceará), 2009.

Presented with the consolidated data, it was found that the investigations carried out most during the year were traumatological, of which 265 (85.76%) related to bodily injuries and 44 (14.24%) to corpus delicti, also specified as supplementary bodily injury investigations (Figure 4). The latter occur when it is not possible for the expert to conclude the examination at the time of the investigation, it being necessary for the subject under investigation to return for new examinations within a period of thirty days, or if he/she is being subjected to treatment, when this has finished.



**Figure 4.** Percentage of traumatological investigations conducted at the Forensic Dentistry Center at the Ceará State Forensic Investigation Division. Fortaleza (Ceará), 2009.

## DISCUSSION

Forensic Dentistry is a specialty which acts in conjunction with other branches of science involved in performing investigations in the search for legally relevant evidence.

Dental investigations may be carried out in the civil, criminal, labor or administrative fields<sup>1-2,8</sup>.

In the present study, it was found that criminal investigations are carried out in institutions such as the Ceará State Forensic Investigation Division, which confirms the statement of Galvão<sup>11</sup> that "The work of a Forensic Dentist in an Institute of Forensic Medicine comprises, amongst others: investigations of the living – bodily injuries and age estimation, investigations of the dead – autopsy and identification and investigation of inanimate objects– Prosthetics and Instruments."

Silva et al.<sup>9</sup> averred that different types of dental investigations are performed by the forensic dentists in the Institutes of Forensic Medicine, with investigations of a traumatological nature or the identification of corpses being the most frequent. The study carried out on the Ceará State Forensic Investigation Division partly confirmed the quoted study, as the traumatological investigations conducted in 2009 were the most frequent, though those performed in order to identify corpses were not so common. In addition to the investigations previously cited, a significant number of investigations were undertaken to establish age estimation.

According to the results of this study, it is possible to state that Dentistry has much to offer in the processes of age verification and despite these findings not having found a large number of investigations into the identification of corpses, it is indispensable in cases of burnt, lacerated bodies, bodies in an advanced stage of decomposition, drowning and victims of mass accidents or bone remains.

In large-scale disasters, the methods used by forensic dentists often produce better results than with forensic medicine as the dental elements and materials used to make prosthetic and orthodontic appliances are less susceptible to deleterious agents and extreme conditions of degradation, such as exposure to high temperatures, humidity and excessive pressure<sup>1,8,12-14</sup>.

The increase in violence, in cases of homicide followed by the concealment of the bodies, incatastrophes both natural and artificial, such as aviation accidents, tsunamis and earthquakes, has created a need for the presence of forensic dentists during identification investigations.

In situations such as those described above, the bodies found, in the vast majority of cases, are in conditions which conventional methods, such as fingerprinting, cannot be employed, in which case the records of patients' dental conditions are used, when adequately recorded on the dental record card<sup>5,13-14</sup>.

As for the age verification process, it has great importance in many situations, such as in processes to determine the age of delinquents and victims of sex crimes where age cannot be confirmed<sup>15</sup>. These are the motives which dictate the performance of such examinations in the Forensic Investigation Division in Fortaleza (Figure 3).

Article 27 of the Criminal Code<sup>16</sup> states that minors under the age of 18 are not criminally responsible and are subject to policies established under special legislation. However, in certain situations, the police authorities are unable to prove the chronological age of the accused and ask for an examination to be carried out to estimate age in order to be able to apply the applicable punishment under the prevailing legislation. Hence the need for dental investigations to be performed upon the dental arches of these individuals.

Moreover, in some cases of rape or indecent assault in which the victim is unable to prove his/her age, the age estimation method using teeth is employed. In this case, if the victim is under the age of consent, the perpetrator of the sex crime will have his/her criminal situation compounded, as determined by articles 215 and 216 of the Criminal Code<sup>16</sup>.

Silva<sup>17</sup> and Gonçalves & Antunes<sup>8</sup> reported on the methods used in this type of investigation, namely: those carried out by means of clinical examination in which one observes the number of unerupted teeth, the eruptive sequence, the chronology of eruption, the overall condition of the teeth (caries, abrasions, wear, restorations) and those carried out by means of x-ray, by observing the stages of tooth mineralization. Oliveira et al.<sup>18</sup> and Cornélio et al.<sup>19</sup> indicated that the x-ray method was the most effective. It is considered to be very practical in terms of obtaining data and is more reliable than those methods that use bone development or even teeth in the stage of eruption. The explanation for this lies in the fact that this method involves less interference from factors which alter eruption, such as gender, race, diet, climate, systemic illnesses, as well as providing information about the teeth from the start of crown formation through to apical closure. According to information provided verbally by a forensic expert at the Ceará State Forensic Investigation Division, although periapical radiography apparatus exists,

forensic dentists are not accustomed to using it for age estimation examinations; the method most frequently used at the present time, for this type of investigation, is the clinical examination, by observing erupted teeth and the chronology of dental eruption. The x-ray method is only used in cases with wider repercussions.

Another type of investigation, in which the importance of the involvement of forensic dentists can be seen, are traumatological investigations. According to the study that was conducted, these were the most frequent. This outcome is possibly due to the increase in the occurrence of traffic accidents and interpersonal aggression and opens the doors for a discussion on the topic. Garbin et al.<sup>20</sup>, Silva et al.<sup>17</sup>, Oliveira et al.<sup>18</sup> and Togna et al.<sup>21</sup> also pointed to these causes being the ones most responsible for facial lesions, although other etiologies may be listed as being responsible for the problem, such as wounds caused by falls or occupational accidents.

Facial lesions merit some attention. They affect the skin, muscles, nerves, bones and teeth and may have esthetic and functional consequences. In addition, they may, for reasons already stated, result in the victims having emotional problems as facial appearance plays an important role in social, economic and cultural relationships and a change in appearance is easily noticed, given that this region is fully visible.

In the study by Garbin et al.<sup>20</sup>, forensic-medical reports were analyzed arising from police incidents relating to physical violence in the family setting, in order to demonstrate possible errors in their preparation, mainly with regard to lesions of dental interest, and the authors verified the existence of professional mistakes at the time of describing the lesions which afflicted the jaws and the lack of knowledge of the nomenclature attributed to the teeth.

Moreover, the high percentage of bodily injury investigations conducted in the Ceará State Forensic Investigation Division in 2009 suggests there is a need for dental surgeons to be installed as a part of the teams in these institutions, with the aim of contributing towards correct procedure, both in terms of the examinations and the preparation of the official reports.

When conducting a corpus delicti examination, as the expert examination to verify bodily injury is known, the forensic dentist must record in detail the lesions present in the tissues of the oral and maxillofacial complex and these must be identified as to type, location, extent, coloring, teeth and dental surfaces involved, the time that they were produced as well as other information that may be deemed necessary<sup>17</sup>.



Supplementary bodily injury examinations correspond to 14.24% of all examinations conducted, per the present study. According to verbal information received from the forensic dentist at the Ceará State Forensic Investigation Division, a conclusion from the examination and the responses to all the issues in the reports produced by the experts is often not possible in the initial examination, leading these professionals to opt for a return visit by these patients for a new investigation within a period of 30 days or subsequent to the conclusion of any treatment to which they may be subjected. This is called a supplementary bodily injury or corpus delicti examination.

In situations such as the one presented above, it is common to request patient dental records from the dental surgeons attending to the victims. These documents should contain all the information related to the clinical care provided, allowing the expert to establish the causality between the lesions treated by the dental surgeon and the facts related to the lesion alleged in court<sup>17</sup>.

Permeating the practice of he/she who responsibly and ethically exercises his/her functions as Expert in the criminal domain, is the consideration of that which is set out in the recently published Code of Dental Ethics approved by article 10 of Chapter IV of Resolution 118/2012, namely it is the duty of this professional, in the absolute interest of the search for the legal truth, to guarantee the impartiality of his/her observations<sup>22</sup>.

## REFERENCES

1. Silveira EMSZSF. Odontologia legal: a importância do DNA para as perícias e peritos. *Saúde, Ética Just.* 2006;11(1/2):12-8.
2. Peres AS, Peres SHCS, Nishida CL, Grandizoli DK, Ribeiro IWJ, Gobbo LG, et al. Peritos e perícias em Odontologia. *Rev Odontol UNICID.* 2007;19(3):320-4.
3. Paranhos LR, Caldas JCF, Iwashita AR, Scanavini MA, Paschini CR. A importância do prontuário odontológico nas perícias de identificação humana. *RFOUPF.* 2009;14(1):14-7.
4. Santos GLA. Odontologia legal no processo investigativo criminal no Brasil. Brasília: Faculdade Fortium; 2009.
5. Vanrell JP. Odontologia legal e antropologia forense. Rio de Janeiro: Guanabara Koogan; 2002.
6. Silva M. Compêndio de odontologia legal. Rio de Janeiro: Médica e Científica; 1997.
7. Conselho Federal de Odontologia. Resolução n. 185,93, de 26 de abril de 1993. Institui os objetivos e competências da Odontologia Legal [texto na Internet]. *Diário Oficial da União*; 1993 Jun 2 [citado 2013 Jan 9]. Disponível em: <[http://www.forp.usp.br/restauradora/etica/rcfo185\\_93.htm#t1cap8sec4](http://www.forp.usp.br/restauradora/etica/rcfo185_93.htm#t1cap8sec4)>.
8. Gonçalves ACS, Antunes JLF. Estimativa da idade em crianças baseada nos estágios de mineralização dos dentes permanentes, com finalidade odontológica. *Odontol Soc.* 1999;1(1/2):55-62.
9. Silva RF, Daruge Júnior E, Pereira SDR, Almeida SM, Oliveira RN. Identificação de cadáver carbonizado utilizando documentação odontológica. *Rev Odonto Ciênc.* 2008;23(1):90-3.
10. Fernandes MM, Bragança DPP, Oliveira OF, Francesquini Júnior L, Daruge Júnior E. O mercado de trabalho para a odontologia nos ministérios públicos. *Odonto (São Bernardo do Campo).* 2009;17(33):13-6.
11. Galvão MF. Importância do cirurgião-dentista nos IML. In: Galvão MF. *Medicina legal* [texto na Internet]. Brasília: Universidade de Brasília; 1998 [2013 Jan 9]. Disponível em: <<http://www.malthus.com.br/artigos.asp?id=135>>.
12. Frari P, Iwashita AR, Caldas JCFG, Scanavini MN, Daruge Júnior E. A importância do odontologista no processo de identificação humana de vítima de desastre em massa. Sugestão de protocolo de exame técnico-pericial. *Odonto (São Bernardo do Campo).* 2008;16(31):38-44.

## CONCLUSION

The present study made it possible for us to understand and publicize the investigations performed during 2009, which has contributed to a better understanding of the specialty of Forensic Dentistry, particularly in the area of Criminal Investigation.

Given the results of this study, there is clearly a need for forensic dental experts to be a part of the team in the institutions where investigations are conducted, as there are examinations and specific notations in the production of technical evidence which only a professional in this area is capable of carrying out.

## Collaborators

RO BANDEIRA performed the collection, analysis and interpretation of the data, a review of the literature and composition of the article. LMB MENEZES directed the study and took part in the composition of the article. PMC OLIVEIRA and AM CORREIA contributed to the review of the literature and the composition of the article.

13. Paranhos LR, Caldas JCF, Iwashita AR, Scanavini MN, Paschini RC. A importância do prontuário odontológico nas perícias de identificação humana. RFOUPF. 2009;14(1):14-7.
14. Nedel F, Nedel AP, Silva RHA, Lund RG. Evaluation of identification cases involving forensic dentistry in the city of Pelotas, RS, Brazil, 2004-2006. Braz J Oral Sci. 2009;8(1):55-8.
15. Oliveira OF, Fernandes MM, Daruge Júnior E, Melani RFH, Paranhos LR. Estimativa da idade por meio de radiografias panorâmicas. RGO - Rev Gaúcha Odontol. 2010;58(2):203-6.
16. VadeMecum. 2ª ed. São Paulo: Editora Saraiva; 2006.
17. Silva RF, Prado MM, Garcia RR, Daruge Júnior E, Daruge E. Atuação profissional do cirurgião-dentista diante da Lei Maria da Penha. Rev Sul-Bras Odontol. 2010;7(1):110-6.
18. Oliveira DAS, Simões OS, Marques JAM, Galvão LCC, Oliveira RN, Musse JO. Avaliação de marcas de mordidas em alimentos produzidas por próteses dentárias. Arq Odontol. 2010;46(1):38-42.
19. Cornélio Neto WS, Cornélio GC, Conceição MB. Estimativa da idade pelos 3º molares através de Raio x: relato de caso. RGO - Rev Gaúcha Odontol. 2006;54(3):230-3.
20. Garbin CAS, Rovida TAS, Garbin AJI, Saliba O, Dossi AP. A importância da descrição de lesões odontológicas nos laudos médico-legais. RPG RevPos-Grad. 2008;15(1):59-64.
21. Togna GRD, Crosato E, Melani RFH, Michel-Crosato E, Biazevic MGH. Uso da Classificação Internacional de Doenças na análise do absenteísmo odontológico. Rev Saúde Pública. 2011;45(3):512-8. doi: 10.1590/S0034-89102011000300009.
22. Conselho Federal de Odontologia. Resolução 118, de 11 maio de 2012. Diário Oficial da União; 2012 Jun 14 [citado 2013 Jan 9]. Disponível em: <[http://cfo.org.br/wp-content/uploads/2009/09/codigo\\_etica.pdf](http://cfo.org.br/wp-content/uploads/2009/09/codigo_etica.pdf)>.

Received on: 25/2/2012

Final version resubmitted on: 9/1/2013

Approved on: 20/3/2013