

Asymptomatic bilateral elongated and mineralized stylohyoid complex. Report of one case

HELLÍADA CHAVES¹, FÁBIO COSTA², DANIEL CAVALCANTE³,
THYCIANA RIBEIRO⁴, DELANE GONDIM¹

ABSTRACT

The stylohyoid process is a cylindrical bony structure surrounded by important anatomical structures including vessels and nerves. Calcification and elongation of the stylohyoid ligament complex over 30 mm may be associated with neck and facial pain, known as Eagle's syndrome. However, a bilateral ossified and elongated stylohyoid complex may be devoid of symptoms. We report a 79-year-old symptom-free female who presented on a routine conventional dental radiographic exam an 80.96 mm pseudoarticulated stylohyoid complex in the left side and an 75.85 mm on the other. On CAT scan, both processes were calcified.

(Rev Med Chile 2013; 141: 793-796).

Key words: Eagle's syndrome; Radiography, panoramic; Tomography, x-ray computed; Temporal bone abnormalities.

Proceso estilohioideo elongado y calcificado asintomático. Presentación de un caso

El proceso estilohioideo es una estructura ósea rodeada por nervios y vasos sanguíneos. La calcificación elongación del ligamento estilohioideo en más de 30 mm puede asociarse a dolor facial y del cuello, conocido como síndrome de Eagle. Sin embargo, esta alteración anatómica puede ser asintomática. Presentamos una mujer asintomática de 79 años a quien se le descubrieron procesos estilohioideo pseudo articulado de 80,96 mm a un lado y 75,85 mm al otro lado, en una radiografía dental convencional. En la tomografía axial computada, ambos procesos estaban calcificados.

The styloid process is a thin cylindrical bony projection that originates from tympanic part of the temporal bone. Stylohyoid complex (SC) is an anatomic structure formed by styloid process, stylohyoid and stylomandibular ligaments, and stylopharyngeus, stylohyoid and styloglossus muscles¹. Adjacent to SC there are diverse nerves (glossopharyngeal, facial, accessory, hypoglossal, vagus) and vessels (internal jugular vein, internal carotid artery)². Normally, the styloid process is a cylindrical, long cartilaginous bone located on the temporal bone no longer than 30 mm³. However, when the SC assumes large

proportions over than 30 mm, it is considered elongated (SCE). Panoramic radiography is useful for detection of an elongated styloid process in patients with or without symptoms⁴. The SCE can be associated to neck and cervicofacial pain which is formerly known as Eagle's syndrome^{1-3,5,6}.

Several reports of Eagle's syndrome are well described in the literature but few cases of symptom-free patients with SC bilaterally elongated and mineralized have been published. Thus, the purpose of this paper was to describe an interesting case of a non-syndromic patient that presented this condition. The present work was approved

¹Center for Studies and Research in Orofacial Pain, Federal University of Ceará, Fortaleza, Brazil.

²Division of Stomatology, Federal University of Ceará, Fortaleza, Brazil.

³Division of Oral Radiology, Catholic Faculty Rainha do Sertão, Brazil.

⁴Department of Clinical Dentistry, Federal University of Ceará, Fortaleza, Brazil.

There was not any financial support for this work.

Recibido el 21 de marzo de 2012, aceptado el 20 de noviembre de 2012.

Correspondence author:
Dr. Thyciana Rodrigues
Ribeiro

Av. Mister Hull 2933, apt
403 AV, CEP: 60.356-000,
Fortaleza, Ceará, Brazil.
Phone number: +55 85
99746688.

E-mail: thyciana_odonto@
yahoo.com.

by the Ethics Committee of the University of Vale do Acaraú (protocol # 808) and the subject gave its informed consent.

Case Report

A 79-year-old systemically healthy female was referred to the Center for Studies and Research in Orofacial Pain of the Federal University of Ceará *Campus Sobral*, Brazil, for dental routine exams. Intraoral inspection revealed normal tissues recovering the edentulous alveolar processes. A panoramic radiography was taken as a screening film after the examination. Radiographic imaging showed bilateral elongation and calcification

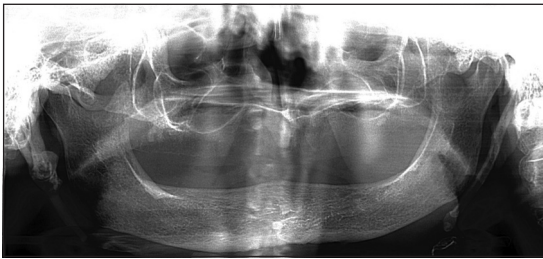


Figure 1. Orthopantomography showing the stylohyoid complex elongated bilaterally.

of the SC measuring 75.85 mm and 80.96 mm for right and left sides respectively (Figure 1). A three-dimensional computed tomographic (CT) reconstruction showed styloid-stylohyoid complexes were over-elongated from the base of the skull plane down to the hyoid bone, with one pseudoarticulation on the right side and segmentation on both sides and confirmed the diagnosis (Figure 2). To exclude the Eagle's syndrome, the tonsillar fossa and cervicofacial region were palpated and did not produce symptoms. Physical examination of the neck region did not reveal abnormalities and the overlying skin was normal with no cervical lymphadenopathy. Upon clinical evaluation, radiographic features, absence of intraoral painful symptoms or cervicofacial discomfort a diagnosis of SC elongation in a non-Eagle's syndrome patient was supposed. Patient's past medical history showed no evidence of systemic diseases. Due to lack of complaints, a non surgical approach was decided in agreement with the patient and the follow-up was uneventful.

Discussion

We have presented a remarkable case of SC elongation in a 79-year-old patient, with typical

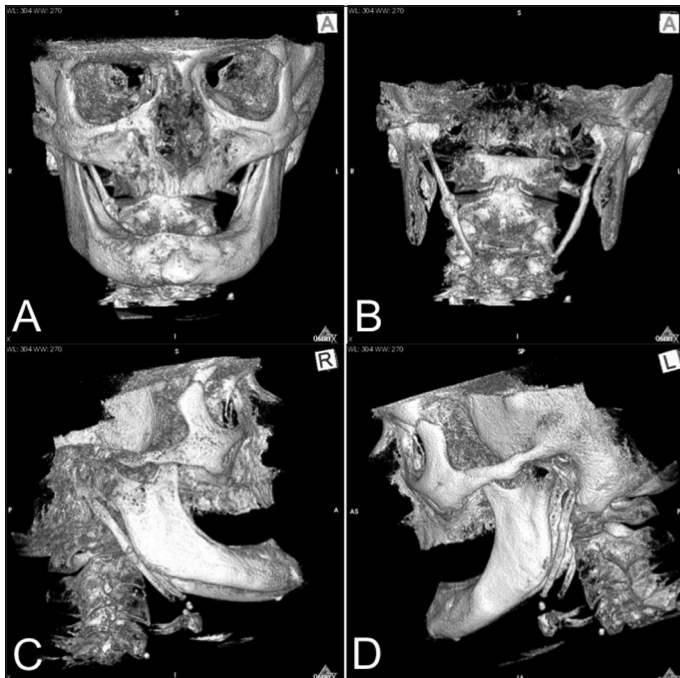


Figure 2. 3D CT showing elongation and ossification of the SC (A, B) with presence of styloid process pseudoarticulated on the right side (C) and segmentation of the styloid process on the left side (D).

radiographic features of bilateral involvement and a 75.85 mm and 80.96 mm for right and left sides respectively of the SC. According to literature, the average length of the styloid process is less than 30 mm, with the normal length ranging from 15.2 mm to 47.7 mm². In a Brazilian study⁶, the mineralization extension varied from 26.1 mm to 65 mm, which was in disagreement with our report. In addition, this study showed that only 4.4% of the elderly population presented the styloid process elongated over than 50 mm.

It has been argued that the SC elongation may be due to low-grade stimulus, surgical trauma, menopause, persistence of mesenchymal elements, growth of the osseous tissue, mechanical stress or trauma during development of styloid process, and more recently extraskeletal (ectopic) calcification or ossification^{3,5}.

When it becomes elongated, commonly neck and cervicofacial painful symptoms are present probably due to compression of the styloid process on neural and vascular structures, and an Eagle's syndrome is defined^{1-3,5,6}. Although unusually, the SC can assume large proportions without symptoms, as observed in the present case and the one reported by Sisman et al³. The ability of a SC to become an extensive structure and not producing symptoms mainly depends on the relationship of the SC with the adjacent nerves and vessels³. As supposed in the current patient, if the styloid process is able to grow with no compression, the condition might remain asymptomatic for a long period of time.

The SC over than 30 mm can cause craniofacial and cervical pain, difficulties in swallowing, secondary glossopharyngeal neuralgia, throat pain, earache, foreign body sensation in throat, pain on changing head position, headache, shoulder pain, sensation of a lump in the throat, and radiating pain into the orbit and maxillary region^{7,8}. An SC elongation may cause symptoms due to compression of the glossopharyngeal, vagus and trigeminal nerves, carotid artery syndrome, hyoid syndrome, or rheumatic styloiditis following pharyngeal infection^{7,9-11}.

The Eagle's syndrome is more frequent in female patients, mainly in individuals younger than 30 years⁸. According to Dao et al¹², this syndrome may be present in either one of two forms: the "classic Eagle's syndrome", which is commonly observed after tonsillectomy surgery, and sympto-

matology similar to cluster headache or migraine due to stimulation of the sympathetic nerve plexus after impingement of the internal or external carotid artery. The diagnosis can usually be made on physical examination by digital palpation of the styloid process in the tonsillar fosse, which exacerbates the pain and with radiographical exams, and injection of an anaesthetic solution into the tonsillar fosse, which relief the symptoms¹³. Surgical approach is usually performed as treatment in affected patients⁷.

Despite of Eagle's syndrome subjects, most asymptomatic patients with elongation of the SC are recognized after routine dental radiographic exams as reported in our case. Langlais et al⁷, proposed a classification of the radiographic appearance of elongated and mineralized SC based on three types of complexes, including type 1 (uninterrupted styloid image), type 2 (styloid process pseudoarticulated with the ossified stylohyoid or stylomandibular ligament), and type 3 (long or short interrupted portions of the styloid process or discontinuous segments of the mineralized ligament). Furthermore, these complexes types were described by a pattern of calcification: calcified outline partially calcified, nodular, and completely calcified. Our report confirms the presence of a pseudo articulation in an extended styloid process, almost entirely ossified in both sides, which is extremely uncommon^{2,7}.

Although orthopantomography is indicated for best visualizing the styloid process, anteroposterior and lateral cefalometric radiography may be valuable². According to Nakamura et al⁸. In conventional radiographs the overlapping of the submandibular area is prone to partly cover the image of the styloid process; also, in the situations where the stylohyal ligament is not completely calcified, correct diagnosis is not always easy and explanation to the patient can be unimpressive in some cases. We performed a three-dimensional computed tomography (3D CT) to confirm the diagnosis of ossification of the stylohyoid ligament and the other relationship structures. It have been reported that 3D CT is a suitable exam for defining anatomic associations, correct size, and angulation of the stylohyoid process².

In cases of styloalgia, effective treatment involves surgical excision or reduction of the styloid process, although pharmacological therapy has been employed¹. For asymptomatic patients, a

closed follow-up is important due to possibility of Eagle's syndrome development after traumatic events^{2,3}.

In conclusion, bilateral elongation and ossification of SC in an asymptomatic patient with pseudoarticulation on the right side and segmentation on both sides, though uncommon, must be included as part of the differential diagnosis for Eagle's syndrome. Our report has confirmed the importance of conventional dental radiographs for initial diagnosis in asymptomatic patients despite recent advanced image approaches. The lack of complaints in our case does not invalidate recommendation for a long-term monitoring, especially when intervening at elderly patients.

References

1. Kim E, Hansen K, Frizzi J. Eagle syndrome: case report and review of the literature. *Ear Nose Throat J* 2008; 11: 631-3.
2. Pereira FL, Filho LI, Pavan AJ, Farah GJ, Gonçalves EA, Veltrini VC, et al. Styloid-stylohyoid syndrome: literature review and case report. *J Oral Maxillofac Surg* 2007; 65: 1346-53.
3. Sisman Y, Gokce C, Sipahioglu M. Bilateral elongated styloid process in an end-stage renal disease patient with peritoneal dialysis: is there any role for ectopic calcification? *Eur J Dent* 2009; 3: 155-7.
4. More CB, Asrani MK. Evaluation of the styloid process on digital panoramic radiographs. *Indian J Radiol Imaging* 2010; 20: 261-5.
5. Gokce C, Sisman Y, Sipahioglu M. Styloid process elongation or Eagle's syndrome: is there any role for ectopic calcification? *Eur J Dent* 2008; 2: 224-8.
6. Rizzatti-Barbosa CM, Ribeiro MC, Silva-Concilio LR, Di Hipolito O, Ambrosano GM. Is an elongated stylohyoid process prevalent in the elderly? A radiographic study in a Brazilian population. *Gerodontol* 2005; 22: 112-5.
7. Prasad KC, Kamath MP, Reddy KJ, Raju K, Agarwal S. Elongated styloid process (Eagle's syndrome): a clinical study. *J Oral Maxillofac Surg* 2002; 60: 171-5.
8. Uysal IO, Atalar MH, Kosar MI, Durmus K. Elongated styloid process associated with nevoid basal cell carcinoma syndrome. *J Craniofac Surg* 2011; 22: 2132-4.
9. Harma R. Stylagia: Clinical experiences of 52 cases. *Acta Otolaryngol* 1967; 224: 149.
10. Moffat DA, Ramsden RT, Shaw HJ. The styloid process syndrome: aetiological factors and surgical management. *J Laryngol Otol* 1977; 91: 279-94.
11. Strauss M, Zohar Y, Laurian N. Elongated styloid process syndrome: intraoral versus external approach for styloid surgery. *Laryngoscope* 1985; 95: 976-9.
12. Dao A, Karnezis S, Lane JS 3rd, Fujitani RM, Saremi F. Eagle syndrome presenting with external carotid artery pseudoaneurysm. *Emerg Radiol* 2011; 18: 263-5.
13. Prabhu LV, Kumar A, Nayak SR, Pai MM, Vadgaonkar R, Krishnamurthy A, Madhan Kumar SJ. An unusually lengthy styloid process. *Singapore Med J* 2007; 48: e34-6.
14. Langlais RP, Miles DA, Van Dis ML. Elongated and mineralized stylohyoid ligament complex: a proposed classification and report of a case of Eagle's syndrome. *Oral Surg Oral Med Oral* 1986; 61: 527-32.
15. Nakamura Y, Fukuda S, Miyashita S, Ohashi M. Diagnosis of the elongated styloid process by three-dimensional computed tomography. *Auris Nasus Larynx* 2002; 29: 55-7.