


Chronic treatment with zoledronic acid increases inflammatory markers in periodontium of rats

Paulo Goberlânio de Barros Silva^{1,2}  | Antonio Ernando Carlos Ferreira Junior¹ | Camila Carvalho de Oliveira¹ | Luiz André Cavalcante Brizeno² | Deysi Viviana Tenazoa Wong³ | Roberto César Pereira Lima Júnior³ | Fabrício Bitú Sousa^{1,2} | Mário Rogério Lima Mota¹ | Ana Paula Negreiros Nunes Alves¹

¹Department of Dental Clinic, Division of Oral Pathology, Faculty of Pharmacy, Dentistry and Nursing, Federal University of Ceará, Fortaleza, Brazil

²Department of Dental Clinic, Unichristus, Fortaleza, Brazil

³Department of Physiology and Pharmacology, Faculty of Medicine, Federal University of Ceara, Fortaleza, Brazil

Correspondence

Paulo Goberlânio de Barros Silva, Division of Oral Pathology, Dental School, Federal University of Ceará, Rodolfo Teófilo, Fortaleza, Ceará, Brazil.
Email: paulo_goberlanio@yahoo.com.br

Funding information

National Council for Scientific and Technological Development (CNPq), Grant/Award Number: 446338/2014-1

Background: Bisphosphonates (BF) rise proinflammatory markers and irreversibly bind to bone. Chronically, BF can lead to an inflammatory status and can increase the local oxidative stress in periodontium. Therefore, the objective of this study was to evaluate whether the chronic infusion of Zoledronic Acid (ZA) increases inflammatory markers in periodontium of rats.

Methods and results: Chronically, infusion therapy was performed with ZA (0.04, 0.2 or 1 mg/kg or saline) by four doses in over a 70-day period to analyze periodontium of the first right inferior molar using histologic, histochemical (toluidine blue), and immunohistochemical (CD68, tumor necrosis factor- α (TNF- α), interleukin-1beta (IL-1 β), inducible nitric oxide synthase (iNOS) and nuclear factor kappa B (NF-kB)) tests. The experiment was replicated (ZA 0.2 mg/kg versus saline) for myeloperoxidase (MPO) assay and dose TNF- α , IL-1 β , malondialdehyde (MDA) and glutathione (GSH) in gingiva of the same tooth. Despite there is no alteration in mast cells ($P = .608$) and CD68 mononuclear-positive cells ($P = .351$), in the periodontium of the ZA-treated group, was observed an increase in the presence of inflammatory cells ($P = .001$) and cytoplasmic immunostaining for TNF- α ($P = .003$), IL-1b ($P = .004$), iNOS ($P = .008$), and NF-kB ($P = .025$). Levels of MPO ($P < .001$), TNF- α ($P = .002$), IL-1 β ($P < .001$), and GSH ($P = .005$) were augmented in gingiva of ZA-treated group but MDA ($P = .993$) levels and NF-kB nuclear staining ($P = .923$) were not altered.

Conclusions: Chronic treatment with ZA increase proinflammatory cytokines and the number of inflammatory cells in periodontium of rats and GSH are expressed probably in a compensatory manner.

KEYWORDS

bisphosphonates, inflammation, oxidative stress, periodontium

1 | INTRODUCTION

Bisphosphonates (BF) are potent antiresorptive drugs and inhibit osteoclast differentiation and maturation. They have therapeutic potential for treatment of bone loss in experimental models of rats

subjected to ligature,¹ although these drugs in high doses lead to bisphosphonate-related osteonecrosis of the jaw (BRONJ).²

BF are related to proinflammatory dysregulation in a dose-dependent manner,³ and an increase in proinflammatory cytokines is

directly associated with BRONJ.⁴ Periodontal disease (PD) is strongly related with BRONJ,⁵ and these two conditions have a common characteristic; both PD and BRONJ have a proinflammatory characteristics.^{4,6}

Chronic treatment with BF leads cellular toxicity in various cell types⁷⁻¹⁰ through an increase in the synthesis of cytokines.⁹ The BF bind to hydroxyapatite irreversibly, and the high time of contact between BF and BF-toxicity-susceptible cells increases toxic effects of BF in these cells and increases the number of dead cells.¹¹

Furthermore, there is a reduction in the phagocytotic activity of macrophages induced by BF,⁹ and the elimination of injured cells can be compromised and lead to high oxidative stress.¹² Then, infiltration of neutrophils can occur leading to high oxidative stress and bone necrosis.⁴

It has been reported that periodontium possesses basal levels of proinflammatory markers¹³; however, chronic BF treatment augments cytokine levels in crevicular fluid.⁵ A previous study suggested the relationship between inflammation and BRONJ,⁴ so if it is correct, why are not all patients treated with BF present BRONJ?

Mammalian has a complex antioxidant system responsible for homeostasis of free radicals.¹³ The reduction in oxidative stress attenuates the PD, reduces cytokine overproduction and inflammatory cells migration, and decreases osteocyte loss.¹ However, the relationship between chronic BF and the expression of inflammatory and pro-oxidant markers in rats "not periodontally compromised" is not known.

Therefore, the objective of this study was to evaluate the changes in inflammatory markers and oxidative stress in healthy periodontal tissue of rats chronically treated with ZA.

2 | MATERIALS AND METHODS

2.1 | Animals, doses, and experimental protocols

After approval by the Ethics Committee on Animal Research of the Faculty of Medicine, Federal University of Ceará (Protocol 26/13), we treated male Wistar rats ($n = 6/\text{group}$) (180-200 g; 60 days old) with three weekly consecutive doses through the intravascular (penile access) infusion of saline and 0.04, 0.20, or 1.00 mg/kg of ZA (days 00, 07, 14). Then, on day 49, an additional dose was infused, and 3 weeks later (day 70), the animals were killed. Their hemimandibles were fixed in neutral formalin 10%. After fixation (24 hours), the hemimandibles were submitted to decalcification (ethylenediaminetetraacetic acid 10%, pH 7.3) for 30 days; histological slides were prepared.⁴

Histological and immunohistochemical analysis were performed, and the experimental protocol was repeated with the infusion of saline or 0.20 mg/kg ZA ($n = 6/\text{group}$). The gingiva of first inferior molar of animals was removed to perform a myeloperoxidase (MPO) assay and dose the tissue with tumor necrosis factor (TNF)- α , IL (interleukin)-1 β , malondialdehyde (MD), and glutathione (GSH).

2.2 | Histological and histochemical reaction

Histological slides (4 μm) were deparaffinized, dehydrated, and stained by conventional hematoxylin-eosin (H&E) technique or toluidine blue (0.1% for 60 seconds) (mast cell evaluation).

2.3 | Immunohistochemical protocol

We performed an immunohistochemical assay for CD68, TNF- α , IL-1 β , inducible nitric oxide synthase (iNOS), and nuclear factor kappa B (NF- κ B). Antigenic recuperation was performed by heat (18 minutes) in a citrate solution with a pH of 6.0. The slides were submitted to peroxidase blocking with a 3% H₂O₂ solution diluted in PBS (phosphate-buffered saline) or in a methanol (NF- κ B) solution for 30 minutes. Subsequently, protein blocking was performed (albumin) (1 hour). The fragments were incubated with primary antibodies CD68 (Dako[®], 1:500, overnight, Dopenhagen, Denmark), TNF- α (Abcam[®], 1:50, 1 hours), IL-1 β (Abcam[®], 1:100, 1 hours, Cambridge, UK), iNOS (Abcam[®], 1:200, overnight), and NF- κ B (SantaCruz[®], 1:200, overnight, Finnell Street Dallas, TX, USA).

Universal immune-peroxidase polymer (Histofine[®] for Dako[®] or Abcam[®] primary antibodies; 30 minutes, Nicherei Biosciences Inc., Tokyo, Japan) or secondary biotinylated anti-rabbit IgG (for primary antibodies Santa Cruz[®]; 30 minutes) plus ABC system (Santa Cruz[®]; 30 minutes) was used. The revelation system in all cases was 5,5-diaminobenzidine tetrahydrochloride (DAB) (Dako[®]).

2.4 | Histological, histochemical, and immunohistochemical analysis

The entire area of periodontium of the first right inferior molar of each rat was analyzed using optical microscopy at 400 \times magnification. To determine the inflammatory profile of the periodontium trough, an dichotomic evaluation of the presence of inflammatory cells (H&E), mast cells (toluidine blue), and mononuclear CD68-positive cells (immunohistochemistry) was performed.

The inflammatory profile of the periodontium was assessed using the following scores defined by the frequency of percentage of cells with cytoplasmic (for TNF- α , IL-1 β , iNOS, and NF- κ B) and nuclear (for NF- κ B) expression of each antibody: (0) no positive cells; (1—mild) 1%-33% of positive cells; (2—moderate) 34%-66% of positive cells; and (3—intense) 67%-100% positive cells.¹⁴ The final score was agreed upon by two observers ($\kappa = 0.892$).

2.5 | MPO assay

The gingiva of the lower first right molar of the rats ($n = 6/\text{group}$) was homogenized in NaPO₄ (0.2 M, pH = 4.7) buffer and centrifuged (2,000 g for 15 minutes). The supernatant was separated to measure the cytokines, and 1 mL of lysing solution NaCl (0.2%) was added to the pellets. The samples were vortexed (30 seconds) and centrifuged (3000 rpm for 15 minutes), and after discarding the supernatant, we added 250 μL of hexadecyltrimethylammonium

bromide (HTAB) buffer. We homogenized the samples (30 seconds, 4°C), centrifuged the suspension (2,200 g/15 minutes), and measured the change in absorbance at 450 nm using a reading solution (5 mg O-dianisidine, 15 µL of 1% H₂O₂, 3 mL phosphate buffer, 27 mL H₂O). The change in absorbance was recorded and plotted on a standard curve of neutrophil density with the obtained data expressed as myeloperoxidase activity (neutrophils/mg of tissue).¹⁵

2.6 | ELISA assay (TNF-α e IL-1β)

TNF-α and IL-1β concentrations were determined by ELISA. Microtiter plates were coated overnight at 4°C with the following mouse antibodies: anti-TNF-α and anti-IL-1β (Dako®, 1:1000, (bovine serum albumin) BSA 1%). After washing (three times) and blocking the plates (BSA 1%, 2 hours), the samples (obtained from the MPO assay supernatant) and standard at various dilutions were incubated at room temperature for 1 hour. The plates were washed three times with buffer and then added the polyclonal secondary antibody (Sigma®, 1:1000, BSA 1%). After further incubation at room temperature for 1 hour, the plates were washed, and 50 µL of avidin-HRP (Abcam®, 1:5000) was added. The color reagent o-phenylenediamine (OPD; Biosystems®, 50 µL, Lincoln Centre Drive Foster City, CA, USA) was added 15 minutes later, and the plates were incubated in the dark at 37°C for 45 minutes for TNF-α and 20 minutes for IL-1β. The enzyme reaction was terminated with H₂SO₄, and the absorbance was measured at 490 nm. The results are expressed as pg/mg of tissue and are reported as the mean ± SE.¹⁵

2.7 | Malondialdehyde assay (MDA)

The gingiva of first right inferior molar of rats (n = 6/group) was homogenized in KCl (1.15%) buffer (100 mg of tissue/1 mL). Then, the samples were centrifuged (4580 g, 15 minutes). We added 100 µL of 7% sodium dodecyl sulfate (SDS) to Eppendorf tubes and incubated the tubes in a water bath (37°C, 30 minutes). Thiobarbituric acid 0.6% (200 µL) was added, and the samples were placed in a water bath at 100°C for 50 minutes. After cooling in ice (5 minutes), we added 100 µL of n-butanol, vortexed (30 seconds), and centrifuged for 20 minutes (580 g, 4°C).

The supernatant of samples (200 µL) and the standard were pipetted in microtiter plates, and the absorbance was measured at 535 nm. The results are expressed as nmol/mg of tissue and reported as mean ± SE.¹⁶

2.8 | Glutathione (GSH)

The gingiva of first right inferior molar of rats (n = 6/group) was homogenized in EDTA 0.02M buffer (100 mg of tissue/1 mL). Then, we transferred 100 µL of the homogenate into different Eppendorf tubes, added 80 µL of H₂O and 20 µL of 50% trichloroacetic acid, and vortexed (30 seconds).

The sample was centrifuged (3000 rpm, 15 minutes), and 100 µL of supernatant was transferred to other Eppendorf tubes along with

100 µL of 0.4 M Tris-EDTA (pH = 8.9) and 10 µL of 0.01 M DTNB (acid 5',5'-dithio-bis(2-nitrobenzoic acid)) and was vortexed (40 seconds).

The mixture (200 µL) and the standard were pipetted into microtiter plates, and the absorbance was measured at 412 nm. The results are expressed as mg of GSH/g of tissue and are reported as the mean ± SE.¹⁶

2.9 | Statistical analysis

Statistical analyses were performed using the Kruskal-Wallis test/Dunn's test or Mann-Whitney test for scores (Median (Minimum-Maximum)) and dosage (mean ± standard mean error) analysis (nonparametric data) and the Chi-squared test (absolute and percentage frequency) for categorical analysis. All the tests were performed using the GraphPad Prism 5.0 software (GraphPad Software, Inc., La Jolla, CA, USA), and a significance level of 5% was used.

3 | RESULTS

3.1 | ZA Chronic treatment increases the number of rats showing inflammatory cells in periodontium

The groups treated with 0.20 mg/kg (n = 5, 83.3%) and 1.00 mg/kg (n = 6, 100.0%) ZA showed a significant number of rats with inflammatory cells in the periodontium (P = .001) compared with saline (n = 1, 16.7%) and the 0.04 mg/kg ZA (n = 0, 0.0%)-treated groups. There was no difference in animals showing mast cells (P = .608) or mononuclear CD68-positive cells in periodontal ligament (P = .351) (Table 1, Figure 1).

3.2 | Chronic treatment with ZA augments the cytoplasm immunostaining for TNF-α, IL-1β, iNOS, and NF-κB in periodontium of rats

The groups treated with ZA exhibited high levels of cytoplasmic TNF-α expression in periodontal cells. The median of TNF-α for the positive cells was 1 (0-2) in saline group, but the groups treated with 0.20 mg/kg (3, 2-3) or 1.00 mg/kg (3, 3-3) ZA exhibited a median of 3 for TNF-α-positive cells, which was significantly greater than in the saline group (P = .003) (Table 1, Figure 2). ZA-treated group with 0.04 mg/kg (median = 2, 1-3) did not differ from the saline group (Table 1, Figure 2).

All groups treated with ZA exhibited high levels of cytoplasmic IL-1β expression in the periodontal cells (median = 3, 3-3) which was significantly greater than in the saline group (median = 2, 2-3) (P = .004) (Table 1, Figure 2).

iNOS immunoexpression was increased in the 0.20 mg/kg and 1.00 mg/kg ZA groups (Median = 3, 3-3) when compared with the saline group (median = 1, 1-2). The number of iNOS-positive periodontal cells in the 0.04 mg/kg ZA-treated group (1.5, 1-2) did not differ from the saline group (Table 1, Figure 2).

	Saline	ZA			P-value
		0.04	0.20	1.00	
Dilated/Ectatic blood vessels	3 (50.0%)	3 (50.0%)	6 (100.0%)	4 (66.7%)	.212*
Resorption of cementum	3 (50.0%)	4 (66.7%)	2 (33.3%)	3 (50.0%)	.721*
Inflammatory cells	1 (16.7%)	0 (0.0%)	5 (83.3%)*	6 (100.0%)*	.001*
Mast cells	2 (50.0%)	4 (66.7%)	5 (83.7%)	3 (50.0%)	.608*
Mononuclear CD68+	0 (0.0%)	2 (33.3%)	3 (50.0%)	3 (50.0%)	.351*
TNF- α	1 (0-2)	2 (1-3)	3 (2-3)**	3 (3-3)**	.003**
IL-1 β	2 (2-3)	3 (3-3)**	3 (3-3)**	3 (3-3)**	.004**
iNOS	1 (1-2)	1.5 (1-2)	3 (3-3)**	3 (3-3)**	.008**
NF-kB					
Nucleus	0 (0-0)	0 (0-0)	0 (0-0)	0 (0-0)	.923**
Cytoplasm	0 (0-0)	0.5 (0-1)	1 (1-1)**	1 (0-2)**	.025**

TABLE 1 Histological and immunohistochemical aspects of the periodontium of animals treated with different doses of zoledronic acid

*Chi-squared test (absolute and percentage frequency), $P < .05$ versus saline and 0.04 mg/kg ZA groups.

**Kruskal-Wallis/Dunn test (Median (minimum-maximum) or mean \pm SE), $P < .05$ versus saline.

Scores = (0) no positive cells; (1—mild) 1%–33% of positive cells; (2—moderate) 34%–66% of positive cells; (3—intense) 67%–100% positive cells.

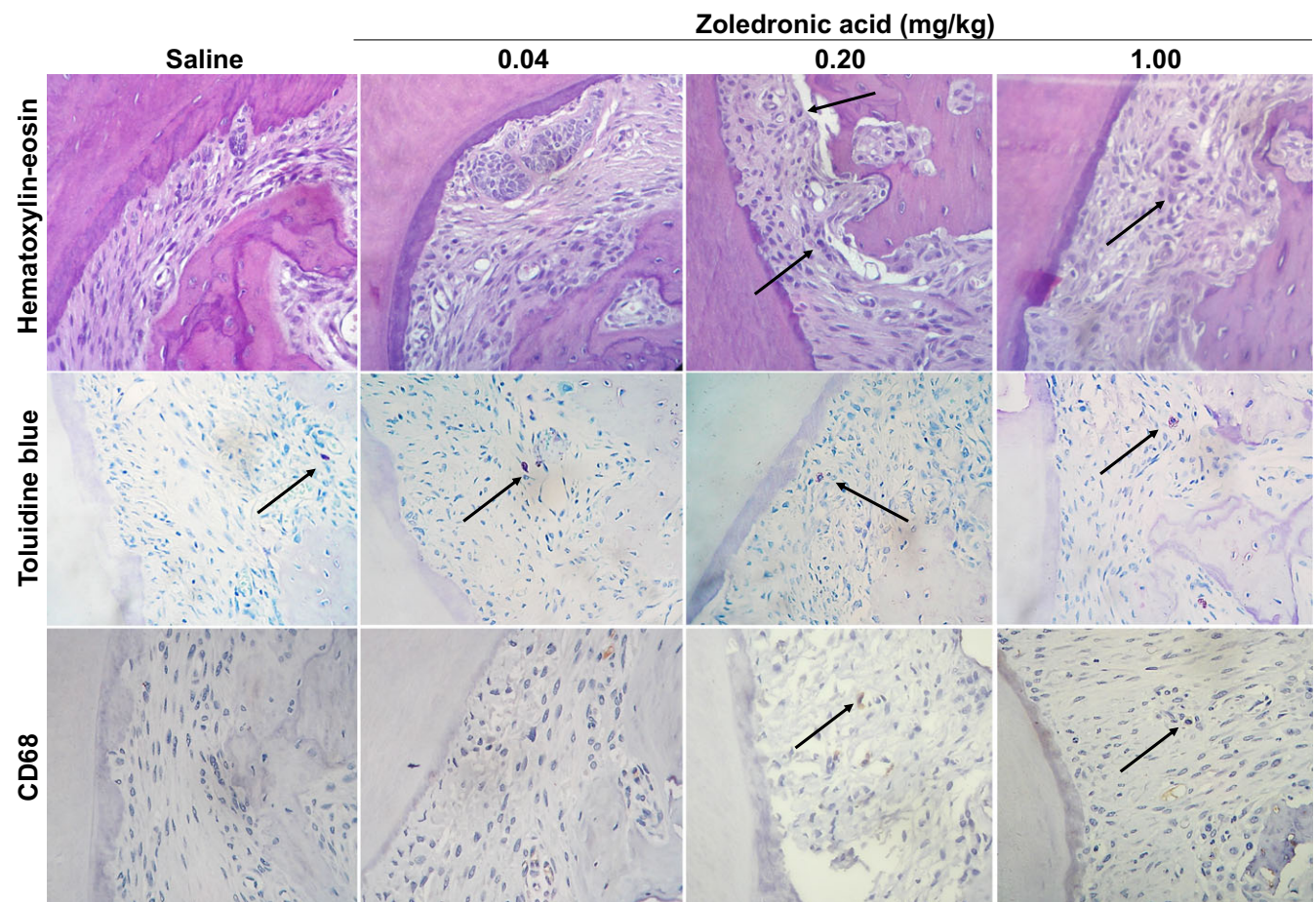


FIGURE 1 Periodontium of rats treated with ZA chronically showing increase in the number of animals with inflammatory cells, however, without augment of mast cells or CD68-positive cells (400 \times)

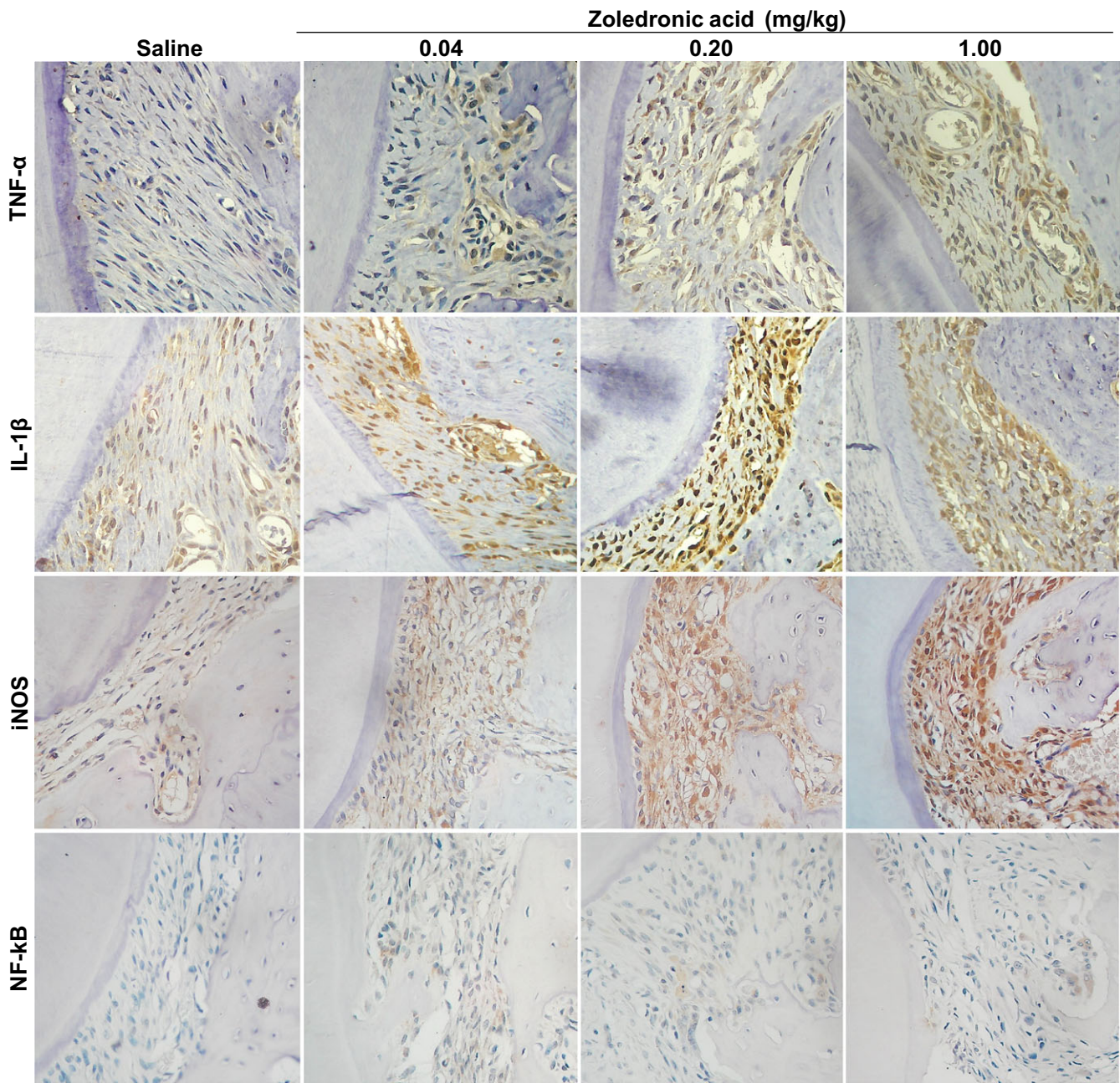


FIGURE 2 Inflammatory profile of rats periodontium treated with ZA chronically showing increase in cytoplasmic expression of TNF- α , IL-1 β , iNOS, and NF-kB. No augment of nuclear NF-kB staining was observed (400 \times)

There are no difference in the nuclear expression of NF-kB ($P = .923$), but the cytoplasmic positivity cells for NF-kB in the periodontium of rats treated with 0.20 mg/kg (median = 1, 1-1) and 1.00 mg/kg (median = 1, 0-2) were significantly greater compared with saline group, in which none of the animals showed immunostaining for this marker ($P = .025$) (Table 1, Figure 2).

3.3 | Chronic treatment with ZA augments MPO activity and levels of TNF- α e IL-1 β in gingiva of rats

The number of neutrophils ($5.7 \pm 1.2 \times 10^3$ neutrophils/mg of tissue) and the TNF- α (281.4 ± 25.6 pg/mg of tissue) and IL-1 β

(115.9 ± 35.4 pg/mg of tissue) levels were significantly augmented in the gingiva of rats treated with 0.20 mg/kg of ZA compared with saline (MPO = $0.0 \pm 0.0 \times 10^3$ neutrophils/mg of tissue, $P < .001$; TNF- α = 10.8 ± 5.3 pg/mg of tissue, $P = .002$; IL-1 β = 3.4 ± 1.7 pg/mf of tissue, $P < .001$) (Figure 3).

3.4 | Chronic treatment with ZA increases in GSH levels but not altered in MDA levels

The MDA levels did not differ in rats treated with 0.20 mg/kg of ZA (MDA = $9.4 \pm 4.4 \times 10^3$ nmol/mg of tissue) when compared with the saline group (MDA = $9.5 \pm 3.7 \times 10^3$ nmol/mg of tissue,

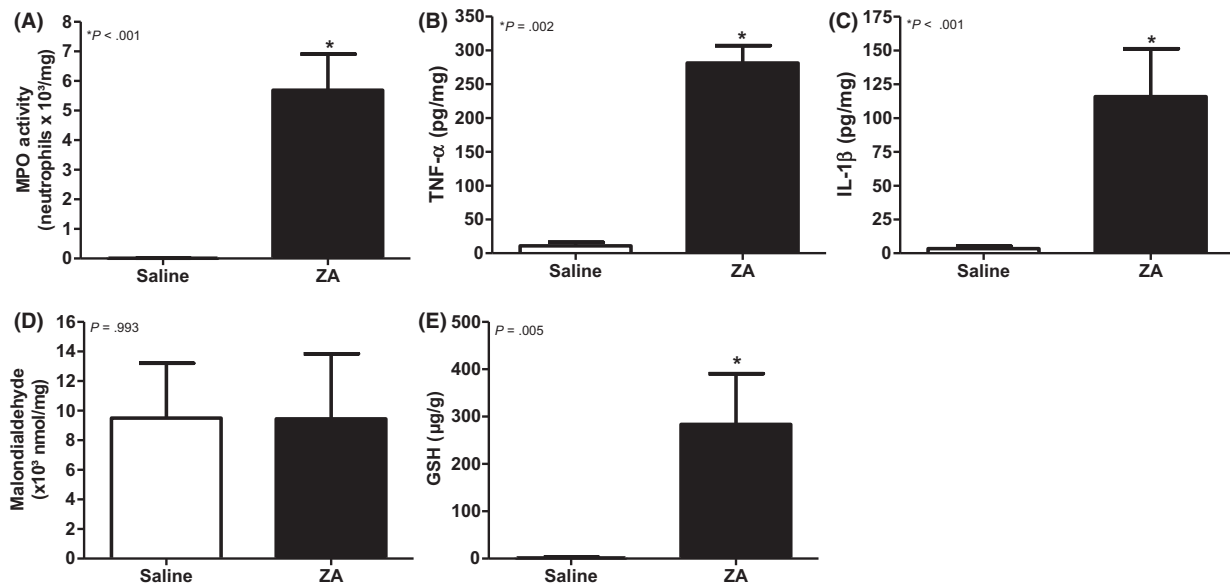


FIGURE 3 Inflammatory and biochemical gingival profiles of the animals treated with ZA chronically demonstrating increase in the MPO activity (A) and TNF- α (B), IL-1 β (C), and GSH (E) without variation in MDA (D) levels

$P = .993$). However, the GSH levels were increased in 0.20 mg/kg of ZA group ($283.7 \pm 106.9 \mu\text{g/g}$ of tissue) compared with the saline group ($1.5 \pm 1.4 \mu\text{g/g}$ of tissue) ($P = .005$) (Figure 3).

4 | DISCUSSION

BF treatment leads some cellular types die or interfere in their metabolism.⁷⁻¹⁰ The cellular toxicity increases in parallel to cytokines overexpression,¹⁷ and the fibroblasts of periodontium are not an exception.¹⁸ Gingival tissue produced high levels of proinflammatory mediators in response to BF, as shown in this study.

The chronic infusion of ZA increases the number of inflammatory cells and TNF- α and IL-1 β levels significantly. This alteration was observed in periodontal cells and in gingiva of the rats treated with ZA with an augmentation of neutrophils. The MPO activity was also significantly enhanced in gingiva of ZA-treated groups likely because TNF- α and IL-1 β are important in the chemotaxis of neutrophils.¹⁹ The induction of some chemokines in a TNF- α -dependent and IL-1 β -dependent manner contributes to an augment of neutrophils and damages locally.^{14,15}

Neutrophils produce high levels of reactive oxygen species (ROS) that contribute to more inflammatory cell migration. Additionally, ZA impairs neutrophil function and reduces neutrophil survival in vitro. When these cells die (after phagocytosis or after their short cell cycle), they liberate ROS, causing vasodilatation.⁷ Additionally, a recent research demonstrated that treatment of gingival fibroblasts with ZA decreases the cell viability, especially when these cells were incubated with IL-1 β .²⁰ This way involves increasing cyclooxygenase 2 (COX-2) and prostaglandin E2 (PGE2) expression and leads to neutrophil migration and augment of oxidative stress.^{14,15}

The augmentation of proinflammatory commonly leads rises in oxidative stress markers, but in this study, it was accompanied by an increase in GSH levels preventing an increase in MDA formation. Bagan²¹ showed that cancer patients treated with intravascular BF have increased oxidized glutathione, but not GSH itself. Nevertheless, these patients have some malignancies that increase the production of ROS per se.²²

Complex antioxidants agents maintain homeostasis of aerobic metabolism. Because the pro-oxidant agents did not exceed the antioxidant systems, there are compensatory mechanisms.²³

BRONJ is a condition directly associated with proinflammatory (TNF- α , IL-1 β , IL-17) markers and iNOS activity,²⁴ and it appears that macrophages and the nuclear activity of NF- κ B are necessary for the pathogenesis of this condition.^{4,17} In this study, an increase in the nuclear expression of NF- κ B and number of rats showing mononuclear CD68-positive cells were not shown in the "healthy periodontium," but we demonstrated the rise of GSH levels.

Overproduction of antioxidants, such as GSH, represses cell apoptosis²⁴ and NF- κ B activation.²⁵ So, the upregulated compensatory antioxidant system can protect the periodontal cells which are suffering damage¹² by ZA-induced cytokines.¹⁷ BF enhance proinflammatory cytokines (TNF- α and IL-1 β), but these drugs increase the synthesis of important antioxidant molecules.¹⁸

Periodontal cells treated with BF produce more OPG (osteoprotegerin)¹⁸ that is directly associated with GSH protection activity (21). Additionally, osteoblasts treated with risedronate increase other antioxidant proteins as Hsp90 (22). Hsp90 is an important antioxidant molecule that decreases ROS formation and peroxidation (23). In eukaryotic cells, Hsp90 is linked to GSH, and it is necessary the cleavage of two proteins to release GSH (24).

Nevertheless, the metabolism of ROS in bone is complex, occasionally paradoxical and need many studies to comprise the rule of

oxidative stress ZA-mediated in pathogenesis of cellular damage ROS-induced (25).

Thus, we showed that chronic infusion of ZA in rats can lead to inflammatory alteration with an increase in proinflammatory markers in gingiva and periodontium. Additionally, we found a significant increase in compensatory GSH levels in gingiva of ZA-treated groups. These data contribute to the hypothesis that the ZA can lead an immune inflammatory disruption and to facilitate the installation of BRONJ.

ACKNOWLEDGEMENT

The authors thank the Laboratory of Pharmacology of Inflammation and Cancer (LAFICA), for the development of this study. The authors also thank the National Council for Scientific and Technological Development (CNPq) for their assistance in this work and for granting scholarships to the graduate student and fund to this research (Universal Protocol number 446338/2014-1).

CONFLICT OF INTEREST

The authors deny any conflict of interest.

AUTHORS CONTRIBUTIONS

Paulo Goberlânio de Barros Silva performed experiments, statistical analysis, and wrote the manuscript. He read and approved the final version. Antonio Ernando Carlos Ferreira Junior and Camila de Oliveira Carvalho performed the experiments and performed the maintenance of animals and histochemical reactions. She read and approved the final version. Luiz André Cavalcante Brizeno and Deysi Viviana Tenazoa Wong were responsible for immunohistochemical reactions. They read and approved the final version. Roberto César Pereira Lima Júnior was responsible for the pharmacological study design, review of the statistical analysis, and writing of the manuscript. He read and approved the final version. Fabrício Bitú Sousa and Mário Rogério Lima Mota were responsible for the pathological study design, review text, and writing of the manuscript. They read and approved the final version. Ana Paula Negreiros Nunes Alves designed the model, guided experiments, reviewed the text, and read and approved the final version.

ORCID

Paulo Goberlânio de Barros Silva  <http://orcid.org/0000-0002-1513-9027>

REFERENCES

- Said F, Ghoul-Mazgar S, Khemiss F, et al. The effect of etidronate on the periodontium of ovariectomized rats. *J Periodontol.* 2012;83:1063-1068.
- Silva PG, Ferreira Junior AE, Teófilo CR, et al. Effect of different doses of zoledronic acid in establishing of bisphosphonate-related osteonecrosis. *Arch Oral Biol.* 2015;60:1237-1245.
- Norton JT, Hayashi T, Crain B, et al. Cutting Edge: nitrogen bisphosphonate-induced inflammation is dependent upon mast cells and IL-1. *J Immunol.* 2012;188:2977-2980.
- Barros Silva PG, de Oliveira CC, Brizeno L, et al. Immune cellular profile of bisphosphonate-related osteonecrosis of the jaw. *Oral Dis* 2016;22:649-657.
- Tsao C, Darby I, Ebeling PR, et al. Oral health risk factors for bisphosphonate-associated jaw osteonecrosis. *J Oral Maxillofac Surg.* 2013;71:1360-1366.
- Lima V, Bezerra MM, Bezerra VBM, et al. Effects of Chlorpromazine on Alveolar Bone Loss in Experimental Periodontal Disease in Rats. *Eur J Oral Sci.* 2000;108:123-129.
- Kuiper JWP, Forster C, Sun C, et al. Zoledronate and pamidronate depress neutrophil functions and survival in mice. *Br J Pharmacol.* 2012;16:532-539.
- Misso G, Porru M, Stoppacciaro A, et al. Evaluation of the in vitro and in vivo antiangiogenic effects of denosumab and zoledronic acid. *Cancer Biol Ther.* 2012;13:1491-1500.
- Scheller EL, Hankenson KD, Reuben JS, et al. Zoledronic acid inhibits macrophage SOCS3 expression and enhances cytokine production. *J Cell Biochem.* 2011;112:3364-3372.
- Lima-Júnior RC, Figueiredo AA, Freitas HC, et al. Involvement of nitric oxide on the pathogenesis of irinotecan-induced intestinal mucositis: role of cytokines on inducible nitric oxide synthase activation. *Cancer Chemother Pharmacol.* 2012;69:931-942.
- Martins CS, Leitão RF, Costa DV, et al. Topical HPMC/S-nitrosoglutathione solution decreases inflammation and bone resorption in experimental periodontal disease in rats. *PLoS ONE.* 2016;26:e0153716.
- Muratsu D, Yoshiga D, Taketomi T. Zoledronic acid enhances lipopolysaccharide-stimulated proinflammatory reactions through controlled expression of SOCS1 in macrophages. *PLoS ONE.* 2013;8:e67906.
- Tipton DA, Seshul BA, Dabbous MK. Effect of bisphosphonates on human gingival fibroblast production of mediators of osteoclastogenesis: RANKL, osteoprotegerin and interleukin-6. *J Periodontol Res.* 2011;46:39-47.
- Graves DT, Jiang Y. Chemokines: a family of chemotactic cytokines. *Crit Rev Oral Biol Med.* 1995;6:109-118.
- Jacobs C, Schramm S, Dirks I, et al. Mechanical loading increases pro-inflammatory effects of nitrogen-containing bisphosphonate in human periodontal fibroblasts. *Clin Oral Investig.* 2017;. doi:10.1007/s00784-017-2168-1
- Bagan J, Sáez GT, Tormos MC, et al. C. Oxidative stress in bisphosphonate-related osteonecrosis of the jaws. *J Oral Pathol Med.* 2014;43:371-377.
- Liou G-Y, Storz P. Reactive oxygen species in cancer. *Free Radic Res.* 2010;44:479-496.
- Halliwell B. Reactive species and antioxidants. Redox biology is a fundamental theme of aerobic life. *Plant Physiol.* 2006;141:312-322.
- Ran Q, Liang H, Gu M, et al. Transgenic mice overexpressing glutathione peroxidase 4 are protected against oxidative stress-induced apoptosis. *J Biol Chem.* 2004;279:55137-55146.
- Post A, Holsboer F, Behl C. Induction of NF-kappaB activity during haloperidol-induced oxidative toxicity in clonal hippocampal cells: suppression of NF-kappaB and neuroprotection by antioxidants. *J Neurosci.* 1998;18:8236-8246.
- Romagnoli C, Marcucci G, Favilli F, et al. Role of GSH/GSSG redox couple in osteogenic activity and osteoclastogenic markers of human osteoblast-like SaOS-2 cells. *FEBS J.* 2013;280:867-879.

22. Romanello M, Bivi N, Pines A, et al. Bisphosphonates activate nucleotide receptors signaling and induce the expression of Hsp90 in osteoblast-like cell lines. *Bone*. 2006;39:739-753.
23. Kim YS, Seo HW, Jung G. Reactive oxygen species promote heat shock protein 90-mediated HBV capsid assembly. *Biochem Biophys Res Commun*. 2015;457:328-333.
24. Nemoto T, Ohara-Nemoto Y, Ota M, et al. Mechanism of dimer formation of the 90-kDa heat-shock protein. *Eur J Biochem*. 1995;233:1-8.
25. Wimalawansa SJ. Nitric oxide and bone. *Ann N Y Acad Sci*. 2010;1192:391-403.

How to cite this article: de Barros Silva PG, Ferreira Junior AEC, de Oliveira CC, et al. Chronic treatment with zoledronic acid increases inflammatory markers in periodontium of rats. *J Oral Pathol Med*. 2017;00:1-8. <https://doi.org/10.1111/jop.12640>