

# Immune cell profile of dental pulp tissue treated with zoledronic acid

P. G. de Barros Silva<sup>1</sup> , M. E. Q. L. Verde<sup>1</sup>, L. A. C. Brizeno<sup>2</sup>, D. V. T. Wong<sup>3</sup>, R. C. P. Lima Júnior<sup>3</sup>, F. B. Sousa<sup>1</sup>, M. R. L. Mota<sup>1</sup> & A. P. N. N. Alves<sup>1</sup>

<sup>1</sup>Department of Dental Clinic, Division of Oral Pathology, Faculty of Pharmacy, Dentistry and Nursing, Federal University of Ceara, Fortaleza, Ceara; <sup>2</sup>Department of Biotechnology, Faculty of Biotechnology, Federal University of Ceara, Fortaleza, Ceara; and <sup>3</sup>Department of Physiology and Pharmacology, Faculty of Medicine, Federal University of Ceara, Fortaleza, Ceara, Brazil

## Abstract

**de Barros Silva PG, Verde MEQL, Brizeno LAC, Wong DVT, Lima Júnior RCP, Sousa FB, Mota MRL, Alves APNN.** Immune cell profile of dental pulp tissue treated with zoledronic acid. *International Endodontic Journal*.

**Aim** To characterize the pulp immune cell profile in the teeth of rats treated with zoledronic acid (ZA).

**Methodology** Male Wistar rats ( $n = 6$  per group) received four intravenous infusions of ZA at doses of 0.04, 0.20 or 1.00 mg kg<sup>-1</sup> ZA or saline (control). On the 70th experimental day, they were euthanized. The first right molar was examined microscopically and submitted to toluidine blue reaction and immunohistochemical for CD68, tumour necrosis Factor (TNF)- $\alpha$ , interleukin (IL)-1 $\beta$ , inducible nitric oxide synthase (iNOS), nuclear factor kappa B (NF-kB) and IL-18 binding protein (IL-18 bp). The presence of ectasic/dilated vessels and inflammatory cells was analysed, and mast cells and mononuclear CD68-positive cells were counted along with the intensity of immunostaining (0–3) for inflammatory markers in

odontoblasts and nonodontoblasts pulp cells. The Kruskal–Wallis/Dunn's test (scores or quantitative data) and the chi-squared test (categorical data) were used (GraphPad Prism 5.0,  $P < 0.05$ ).

**Results** There was no differences in the number of animals exhibiting dilated/ectasic blood vessels ( $P = 0.242$ ) and inflammatory cells ( $P = 0.489$ ) or in the number of mast cells ( $P = 1.000$ ). However, there was an increase in mononuclear CD68-positive cells ( $P = 0.026$ ), immunostaining of TNF- $\alpha$  ( $P = 0.020$ ), IL-1 $\beta$  ( $P = 0.027$ ) and iNOS ( $P = 0.001$ ) in odontoblasts, and IL-1 $\beta$  ( $P = 0.013$ ) in nonodontoblast pulp cells dose-dependently. NFkB (nucleus and cytoplasm) and IL-18 bp did not differ between groups.

**Conclusion** ZA modified the immune cell profile in the dental pulp, increasing the number of macrophages and expression of pro-inflammatory markers independent of NFkB.

**Keywords:** acute-phase reaction, dental pulp, inflammation, zoledronic acid.

Received 14 March 2016; accepted 7 December 2016

Correspondence: Paulo Goberlânio de Barros Silva, Division of Oral Pathology, Department of Clinical Dentistry, School of Dentistry, Federal University of Ceará, Alexandre Barauna Street, 949, Rodolfo Teófilo, 60430-160 Fortaleza, Ceará, Brazil (Tel.: +55 85 3366 8421; +55 85 8705 7151; fax: +55 85 3366 8421; e-mail: paulo\_goberlanio@yahoo.com.br).

## Introduction

Zoledronic acid (ZA) is a third-generation amino-bisphosphonate. It is an analogue of endogenous pyrophosphate and has an antiresorptive power more than 1000 times greater than that of etidronate, the first bisphosphonate used (Oizumi *et al.* 2009). Due to its potency, high-dose ZA is used for the treatment of diseases such as metastatic cancers of the bone (Silverman & Landesberg 2009). However, this drug has

considerable toxicity and is associated with bisphosphonate-related osteonecrosis of the jaws (BRONJ).

ZA is directly toxic to several groups of cells, such as epithelial cells, fibroblasts (Scheper *et al.* 2009), osteoblasts (Naidu *et al.* 2008), macrophages (Scheller *et al.* 2011), neutrophils (Kuiper *et al.* 2012) and endothelial cells (Misso *et al.* 2012), and also impairs the maturation of myeloid cells (Wolf *et al.* 2006). Nevertheless, little is known about its effect on dental pulp cells.

ZA, like sodium alendronate (Hiraga *et al.* 2010), can lead to dental teratogenicity, and it alters molar eruption and tooth matrix formation, stimulates odontoclastic resorption and induces denticle and odontoma formation (Massa *et al.* 2006). At low concentrations, ZA increases collagen type I expression. At high concentrations, it affects phosphatase alkaline synthesis and alters the cellular morphology of odontoblasts (Basso *et al.* 2013). ZA also time-dependently reduces cellular viability, proliferation and protein synthesis in pulp cells (Cvikl *et al.* 2011).

Tooth physiology involves several events that depend on complex interactions between inflammatory cytokine and protein levels (Rakian *et al.* 2013). In classical experimental models, amino bisphosphonates increase levels of TNF- $\alpha$  and IL-1 $\beta$  (Norton *et al.* 2012), which are important cytokines of the pathogenesis of pulpitis (ElSalhy *et al.* 2013).

Pulpitis is greatly influenced by variations in cytokine levels. Increases in proinflammatory cytokines (Pezelj-ribaric *et al.* 2002) are related to the development of pulpitis and necrosis (Huang *et al.* 1999, ElSalhy *et al.* 2013). This is particularly important when there is a systemic proinflammatory stimulus, such as pharmacological treatments or dental caries (Zadik *et al.* 2010).

Odontoblasts and nonodontoblast cells can respond to caries (Horst *et al.* 2011) by increasing the production of IL-8, TNF (Veerayutthwilai *et al.* 2007) and matrix metalloproteinase (MMP; Accorsi-Mendonça *et al.* 2013). When this process is added to ZA infusion (Cvikl *et al.* 2011), there may be further increases in cytokine production, culminating in pulpitis.

Caution is suggested during the endodontic treatment of patients prescribed bisphosphonates due to the risk of BRONJ (Moinzadeh *et al.* 2013). Endodontic treatment elevates the risk of BRONJ 5.5-fold (Barasch *et al.* 2011), and there are some case reports of BRONJ induced by pulp and periapical diseases (Katz 2005, Wigler *et al.* 2013). The major risk factor for

BRONJ is tooth extraction, but ZA infusion generates a paradox: ZA can elevate the risk of developing pulpitis, which requires endodontic treatment, which is a conservative approach in the prevention of BRONJ. However, endodontic treatment also increases the risk of BRONJ. There are no studies characterizing the immune cell profile in the dental pulp of rats treated with bisphosphonates.

In the light of the role of ZA-dependent cytokine overproduction and ZA's ability to modulate the immune response *in vivo*, the objective of this study was to characterize the pulp immune cell profile in the teeth of rats treated with ZA, through a histological and immunohistochemical study.

## Materials and methods

### Sample size calculation

Using the research by Cvikl *et al.* (2011) that showed a reduction in the rate of protein synthesis in dental pulp-derived cells treated with ZA 30  $\mu\text{mol mL}^{-1}$  by 24 h ( $75.2 \pm 7.1\%$ ) or 48 h ( $44.1 \pm 19.3\%$ ), a power of 90% and a confidence of 95% were adopted to define a sample of five animals (*t*-test). This calculation was based in the hypothesis that ZA chronic infusion modifies the biology of the dental pulp. Due to the possibility of sample loss during the study, a 20% increase in the number of animals was planned. So six animals in each group were used ( $n = 6/\text{group}$ ).

### Animals, doses and experimental protocols

Rats ( $n = 6/\text{group}$ ) received three consecutive weekly intravascular (penile access) infusions of saline or 0.04, 0.20 or 1.00  $\text{mg kg}^{-1}$  of ZA. These doses were calculated by software Dose Calculator provided free by the Food and Drug Administration (<http://www.accessdata.fda.gov>). Body weight and surface area were the parameters used for pharmacological conversion of the human dose of ZA for the animals. The mensal dose (4 mg) used to treat multiple myeloma was calculated to be 0.60  $\text{mg kg}^{-1}$  for the Wistar rats and divided into three weekly administrations of 0.20  $\text{mg kg}^{-1}$ . Then, a dose-response curve was calculated with three values: 0.20  $\text{mg kg}^{-1}$ , five times greater (1.00  $\text{mg kg}^{-1}$ ) and five times less (0.04  $\text{mg kg}^{-1}$ ; Silva *et al.* 2015).

The infusion was performed on days 00, 07 and 14; on day 49, an additional dose was given; and

3 weeks later (day 70), the animals were sacrificed, and the hemi-mandibles were fixed in 10% neutral buffered formalin (Ethics Protocol: 26/13).

After fixation (24 h), the hemi-mandibles were decalcified (ethylenediaminetetraacetic acid 10%, pH 7.3) for 30 days to prepare the tissue for microscopic slides.

### Histological and histochemical assays

Microscopic slides (4 µm) were deparaffinized, dehydrated and cored by the conventional haematoxylin and eosin (H&E) method for histological analysis. Hydrated tissue sections (4 µm) were immersed in a 0.1% toluidine blue solution (in 0.9% sodium chloride) for 60 s for histochemical assays.

### Immunohistochemical assay

After deparaffinization and rehydration, tissue sections (2.5 µm) were used in immunohistochemical assays. Antigenic recuperation was performed by heat in citrate solution (pH 6.0). After reaching room temperature, the slides were blocked in peroxidase with 3% H<sub>2</sub>O<sub>2</sub> and diluted in PBS (phosphate-buffered saline) or methanol solution (only for NF-κB) for 30 min.

After blocking with albumin for 1 h, the slides were incubated with the following primary antibodies: CD68 (Dako®, Copenhagen, Denmark; 1:500 overnight), Tumor Necrosis Factor (TNF)-α (Abcam®, Cambridge, UK; 1 : 50 for 1 h), Interleukin (IL)-1β (Abcam®, 1 : 100 for 1 h), Inducible Nitric Oxide Synthase (iNOS; Abcam®, 1 : 200 overnight), Nuclear Factor kappa B (NF-κB; Santa Cruz®, Finnell Street Dallas, TX, USA; 1 : 200 overnight) and IL-18 binding protein (IL-18 bp; Santa Cruz®, 1 : 100 overnight).

Universal Immune-peroxidase Polymer (Histofine®; [Nichei Biosciences Inc., Tokyo, Japan] for Dako® or Abcam® primary antibodies; 30 min) or secondary biotinylated anti-rabbit IgG (for primary antibodies Santa Cruz®; 30 min) plus ABC System (Santa Cruz®; 30 min) was used. 5,5-diaminobenzidine tetra hydrochloride (DAB) was used to identify positive cells (Dako®).

### Histological, histochemical and immunohistochemical analysis

The right mandibular first molar of each rat was analysed by optic microscopy at 400× magnification

(five microscopic fields per tooth). To characterize the cell profile of the pulp by H&E, the presence of ectasic/dilated vessels and inflammatory cells was evaluated. The total CD68-positive mononuclear cells (IHC) and mast cells in this tooth were also counted.

To characterize the inflammatory profile of the pulp, the right mandibular first molar was evaluated, and the percentage of odontoblast and nonodontoblast cells (mesenchymal cells, such as fibroblasts and inflammatory cells) with cytoplasmic (and nuclear for NF-κB) expression of each antibody was characterized as (0) no positive cells; (1 – mild) 1–33% of positive cells; (2 – moderate) 34–66% of positive cells; and (3 – intense) 67–100% positive cells. The final score was that agreed upon by two observers (kappa = 0.921; Etemad-Moghadam *et al.* 2009).

### Statistical analysis

Kruskal–Wallis and Dunn's post-tests were used for scores (Median (Minimum-Maximum)) or mean (mean ± standard mean error) analysis; the chi-squared test (absolute and percentage frequency of the animals) was used for categorical analysis in GraphPad Prism 5.0 software (GraphPad Software, Inc., La Jolla, CA, USA; *P* < 0.05).

### Power size calculation

Based on the mean number of mononuclear CD68+ positive cells that were found in the dental pulp of the 1.00 mg kg<sup>-1</sup> ZA-treated group (2.3 ± 1.7) in relation to the saline group (0.0 ± 0.0) and considering the sample of six animals per group (*n* = 6), a power of 91.2% to reject the null hypothesis of this study was calculated (*t*-test).

## Results

### Effect of ZA in the dental pulp

In the pulp of animals treated with saline or ZA (0.04, 0.20 or 1.00 mg kg<sup>-1</sup>), there were no significant differences between the four groups. The number of animals exhibiting dilated and ectasic blood vessels (*P* = 0.242) or inflammatory cells (*P* = 0.489) was similar in all groups (Table 1, Fig. 1).

The group given the highest dose of ZA (1.00 mg kg<sup>-1</sup>; 2.3 ± 1.7) had significantly more mononuclear CD68-positive cells than the saline group (0.0 ± 0.0) (*P* = 0.001) although there is no

**Table 1** Histological, histochemical and immunohistochemical profile of molar dental pulp in rats treated with ZA or saline

|                                   | ZA (mg kg <sup>-1</sup> ) |                      |                      |                        | P-Value            |
|-----------------------------------|---------------------------|----------------------|----------------------|------------------------|--------------------|
|                                   | Saline                    | 0.04                 | 0.20                 | 1.00                   |                    |
| Ectasic/Dilated blood vessels     | 6 (100.0%)                | 4 (66.7%)            | 5 (83.3%)            | 6 (100.0%)             | 0.242 <sup>a</sup> |
| Inflammatory cells                | 3 (50.0%)                 | 5 (83.3%)            | 2 (33.3%)            | 3 (50.0%)              | 0.489 <sup>a</sup> |
| Mononuclear CD68 <sup>+</sup>     | 0.0 ± 0.0                 | 0.7 ± 0.3            | 0.5 ± 0.4            | 2.3 ± 1.7 <sup>†</sup> | 0.026 <sup>b</sup> |
| Mast cells                        | 0.0 ± 0.0                 | 0.0 ± 0.0            | 0.0 ± 0.0            | 0.0 ± 0.0              | 1.000 <sup>b</sup> |
| Odontoblasts                      |                           |                      |                      |                        |                    |
| TNF- $\alpha$                     | 0 (0–1)                   | 3 (2–3) <sup>†</sup> | 3 (2–3) <sup>†</sup> | 3 (1–3) <sup>†</sup>   | 0.020 <sup>b</sup> |
| IL-1 $\beta$                      | 3 (2–3)                   | 3 (2–3)              | 3 (3–3) <sup>†</sup> | 3 (3–3) <sup>†</sup>   | 0.027 <sup>b</sup> |
| iNOS                              | 0 (0–1)                   | 3 (2–3) <sup>†</sup> | 3 (3–3) <sup>†</sup> | 3 (3–3) <sup>†</sup>   | 0.001 <sup>b</sup> |
| IL-18 bp                          | 0 (0–0)                   | 0 (0–0)              | 0 (0–0)              | 0 (0–1)                | 0.572 <sup>b</sup> |
| NF-kB                             |                           |                      |                      |                        |                    |
| Nucleus                           | 0 (0–0)                   | 0 (0–0)              | 0 (0–0)              | 0 (0–0)                | 1.000 <sup>b</sup> |
| Cytoplasm                         | 3 (2–3)                   | 3 (3–3)              | 3 (3–3)              | 3 (3–3)                | 0.507 <sup>b</sup> |
| Nonodontoblasts Dental pulp cells |                           |                      |                      |                        |                    |
| TNF- $\alpha$                     | 0 (0–2)                   | 1.5 (0–3)            | 1 (1–2)              | 2 (1–3)                | 0.162 <sup>b</sup> |
| IL-1 $\beta$                      | 2 (1–2)                   | 3 (2–3)              | 3 (2–3)              | 3 (3–3) <sup>†</sup>   | 0.013 <sup>b</sup> |
| iNOS                              | 0 (0–1)                   | 0.5 (0–1)            | 2 (1–3)              | 1 (1–2)                | 0.250 <sup>b</sup> |
| IL-18 bp                          | 0 (0–0)                   | 0 (0–0)              | 0 (0–0)              | 0 (0–0)                | 1.000 <sup>b</sup> |
| NF-kB                             |                           |                      |                      |                        |                    |
| Nucleus                           | 0 (0–0)                   | 0 (0–0)              | 0 (0–0)              | 0 (0–0)                | 1.000 <sup>b</sup> |
| Cytoplasm                         | 0 (0–0)                   | 0 (0–0)              | 0 (0–0)              | 0 (0–0)                | 1.000 <sup>b</sup> |

<sup>a</sup>Chi-square (data showed as absolute and percentage frequency), \* $P < 0.05$  versus Saline.

<sup>b</sup>Kruskal–Wallis/Dunn Test (Median (Minimum–Maximum)). <sup>†</sup> $P < 0.05$  versus Saline.

Scores = (0) no positive cells; (1 – mild) 1–33% of positive cells; (2 – moderate) 34–66% of positive cells; (3 – intense) 67–100% positive cells.

difference in the number of these cells in the groups treated with 0.04 mg kg<sup>-1</sup> (0.7 ± 0.3) or 0.20 mg kg<sup>-1</sup> (0.5 ± 0.4) of ZA versus saline. No teeth had mast cells in the pulp ( $P = 1.000$ ; Table 1, Fig. 1).

### Effect of ZA in odontoblasts

The groups treated with ZA exhibited high levels of TNF- $\alpha$  expression in the cytoplasm of odontoblasts. The saline group had a median of 0 (0–1) TNF- $\alpha$ -positive cells, but the groups treated with 0.04 mg kg<sup>-1</sup> (3, 2–3), 0.20 mg kg<sup>-1</sup> (3, 2–3) or 1.00 mg kg<sup>-1</sup> (3, 1–3) ZA exhibited a median of three TNF- $\alpha$ -positive cells, which was significantly higher than the saline group ( $P = 0.020$ ; Table 1, Fig. 2).

The number of IL-1 $\beta$ -positive odontoblastic cells did not differ between the saline (3, 2–3) or 0.04 mg kg<sup>-1</sup> ZA groups (3, 2–3). However, the number of IL-1 $\beta$ -positive odontoblasts was significantly higher in the 0.20 mg kg<sup>-1</sup> (3, 3–3) and 1.00 mg kg<sup>-1</sup> (3, 3–3) ZA groups compared with the saline group ( $P = 0.027$ ; Table 1, Fig. 2).

iNOS immunoeexpression was increased in all groups treated with ZA. The number of iNOS-positive

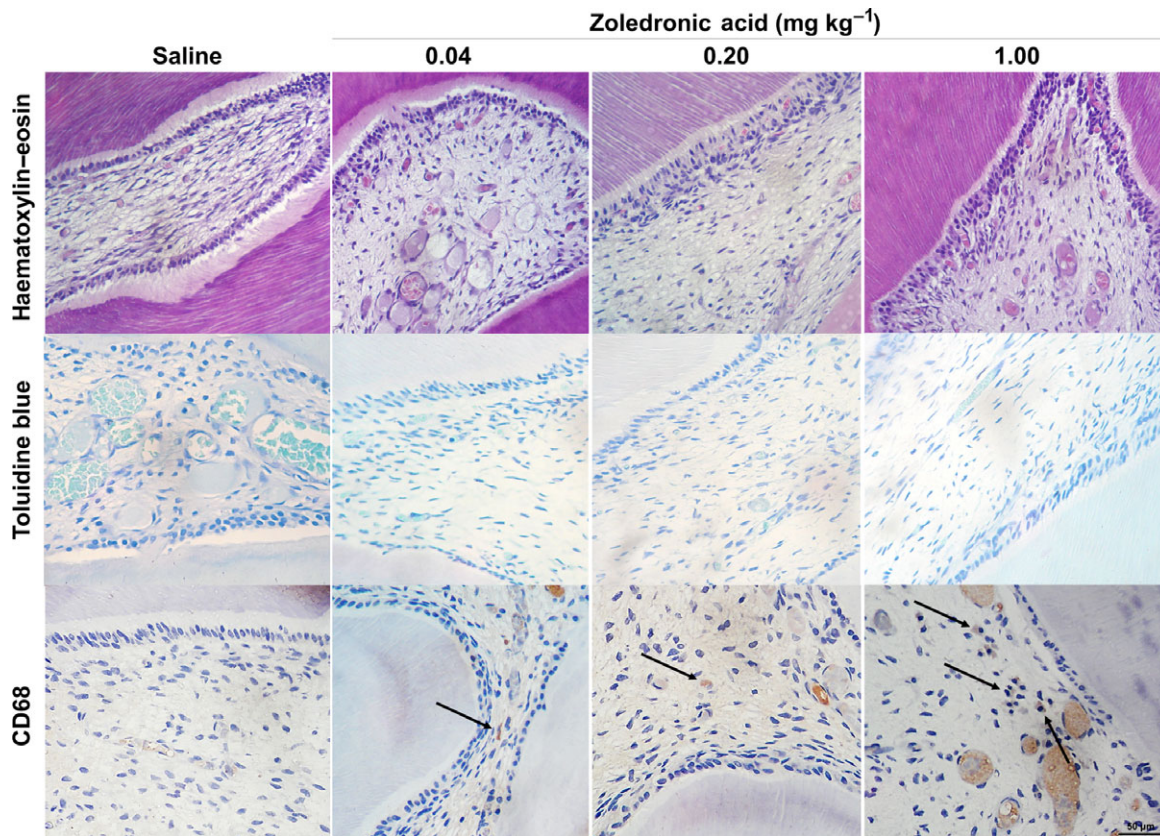
odontoblasts in the saline group (0, 0–1) was significantly lower than in the 0.04 mg kg<sup>-1</sup> (3, 2–3), 0.20 mg kg<sup>-1</sup> (3, 3–3) and 1.00 mg kg<sup>-1</sup> (3, 3–3) ZA-treated groups ( $P = 0.001$ ; Table 1, Fig. 2).

Odontoblasts showed no immunostaining for IL-18 bp ( $P = 0.572$ ) or nuclear immunostaining for NF-kB ( $P = 1.000$ ). However, the odontoblasts in all groups had 100% cytoplasmic immunostaining for NF-kB ( $P = 0.507$ ; Table 1, Fig. 2).

### Chronic treatment with ZA increases IL-1 $\beta$ in nonodontoblast pulp cells

In nonodontoblast pulp cells, the levels of immunostaining for TNF- $\alpha$  were equal for groups treated with saline (0, 0–2) and 0.04 mg kg<sup>-1</sup> (1.5, 0–3), 0.20 mg kg<sup>-1</sup> (1, 1–2) and 1.00 mg kg<sup>-1</sup> ZA (2, 1–3;  $P = 0.162$ ; Table 1, Fig. 2).

The IL-1 $\beta$ -positive nonodontoblast cells did not differ between the saline group (1, 1–2), 0.04 mg.kg<sup>-1</sup> ZA-treated group (3, 2–3) or 0.20 mg.kg<sup>-1</sup> (3, 2–3) ZA-treated group. However, the median number of these cells was significantly higher in the 1.00 mg kg<sup>-1</sup> (3, 3–3) group ( $P = 0.013$ ; Table 1, Fig. 2).



**Figure 1** Cellular profile of dental pulp of rats chronically treated with different doses of ZA shows no modification in histological profile or the number of mast cells but an increase in the number of mononuclear CD68-positive cells in the group treated with 1.00 mg kg<sup>-1</sup> ZA compared with the group treated with saline (400x).

There was no difference in iNOS in nonodontoblast pulp cells in the four groups ( $P = 0.250$ ), and none of these cells was positive for IL-18 bp ( $P = 1.000$ ) or NF- $\kappa$ B (nucleus,  $P = 1.000$ ; cytoplasm,  $P = 1.000$ ; Table 1, Fig. 2).

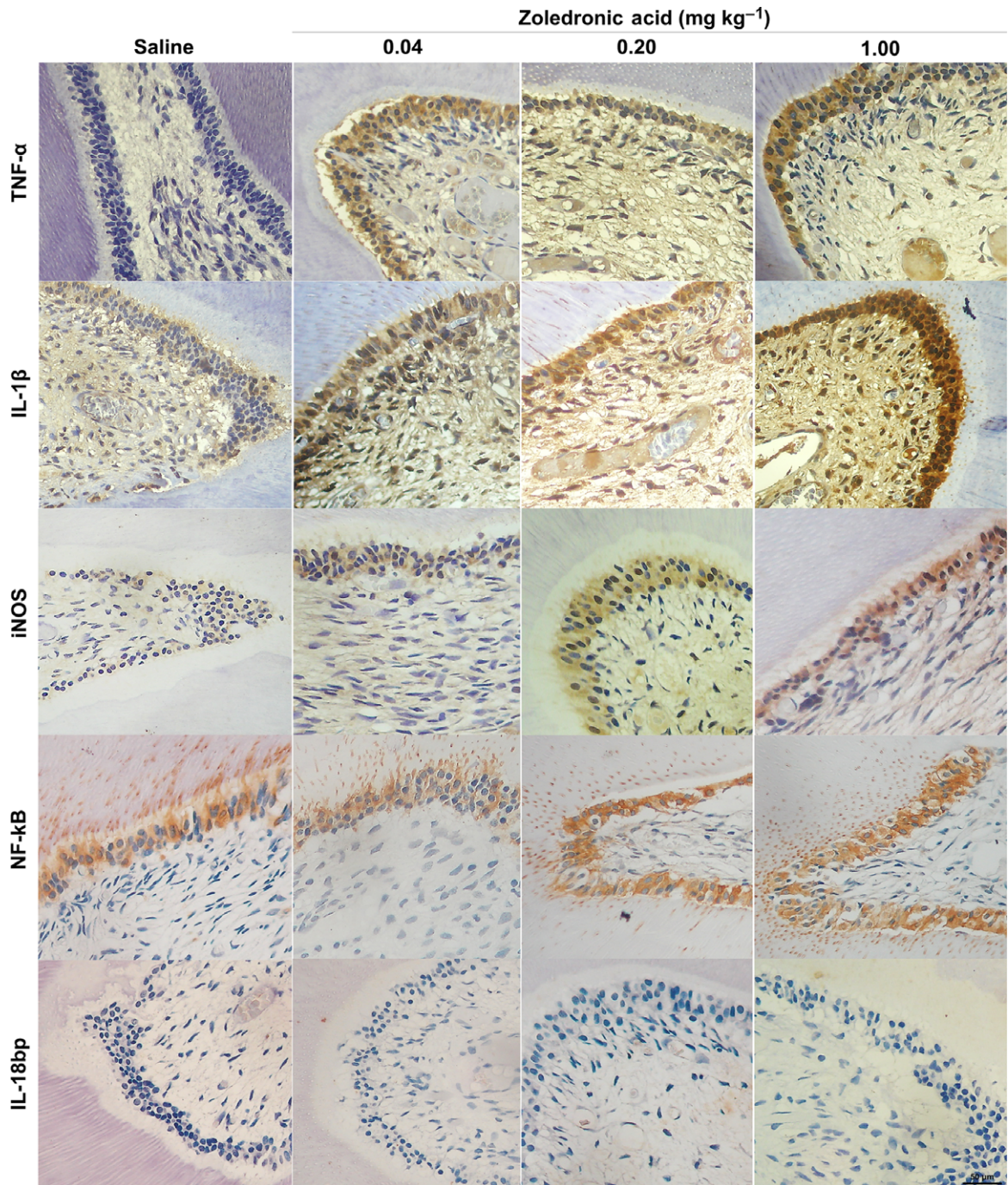
## Discussion

ZA is a toxic drug that is used at high doses for the treatment of bone metastases. ZA can deregulate the immune system and increase the number of inflammatory cells and levels of cytokines (Rossini *et al.* 2012a,b, Norton *et al.* 2012, Welton *et al.* 2013).

Mast cells are poorly visualized in the dental pulp by histochemical methods, and their presence is therefore uncertain. The role of mast cells in pulp diseases is unclear (Bruno *et al.* 2010), but macrophages and dendritic cells, which are mononuclear

and CD68 positive, are common cells that appear in the development and normal physiology of the pulp (Iwasaki *et al.* 2011). In this study, there were a significant number of macrophages in the pulp of rats treated with the highest dose of ZA (1.00 mg kg<sup>-1</sup>). Macrophages have scavenger receptors (Harre *et al.* 2012) that recognize apoptotic cells, and they have an important role in defence against caries: macrophages accumulate in the pulp adjacent to caries-affected regions (Kamal *et al.* 1997) and phagocytose apoptotic cells (Nishikawa & Sasaki 1999). These cells can serve as antigen-presenting cells (APC) and migrate to the apical region of teeth (Rungvechvuttivittaya *et al.* 1998), where they accumulate in response to local overexpression of MCP-1/CCR6 and generate apical granulomas (Liu *et al.* 2014).

An increase in TNF- $\alpha$  and IL-1 $\beta$  levels was observed. These cytokines are important constitutively expressed markers in the pulp, and they can



**Figure 2** Cytokine profile shows an increase in the number of TNF- $\alpha$ -, IL-1 $\beta$ - and iNOS-positive immunostained odontoblasts and nonodontoblast dental cells in ZA-treated groups, no changes in constitutive cytoplasmic NF-kB expression in odontoblasts and an absence of IL-18 bp in all groups (400 $\times$ ).

activate the death domains in pulp cells, stimulating macrophage infiltration and activation (Ohazama *et al.* 2003, Paula-Silva *et al.* 2009). Therefore,

these cytokines may play a role in the increased macrophage number in one of the ZA-treated groups.

There was no significant difference in iNOS expression in nonodontoblast pulp cells between treatment groups, but the odontoblasts of ZA-treated rats were associated with iNOS overexpression. iNOS is only present in inflamed pulps and not in healthy pulps (Di Nardo Di Maio *et al.* 2004). Odontoblasts are important cells that activate this enzyme in response to caries (Veerayutthwilai *et al.* 2007, Farges *et al.* 2015). The iNOS staining may reflect hyperaemia or a state of pulpitis (Di Nardo Di Maio *et al.* 2004, Veerayutthwilai *et al.* 2007, Farges *et al.* 2015). TNF- $\alpha$  and IL-1 $\beta$  (increased in this study) may be partially responsible for the modulation of iNOS activity (Bakker *et al.* 2009).

ZA did not cause direct toxicity to dental pulp cells. High concentrations of this drug are needed to cause this effect, but tissue damage increases with time (Cvikl *et al.* 2011).

In the present *in vivo* study, the ZA dose was converted from human dose to rats. Cvikl *et al.* (2011) used *in vitro* empirical doses of 30 or 100  $\mu\text{mol mL}^{-1}$  to identify the toxic dose-dependent effect of ZA in dental pulp cells. So, the comparison of these two protocols is not possible due to the difficulty in demonstrating the real concentration of ZA in the pulp cells of rat's teeth.

The free (not incorporated) ZA is the most associated with ZA toxicity in dental pulp cells (Cvikl *et al.* 2011). In bone, the toxicity of bisphosphonates appears, whilst osteoclasts demineralization releases the incorporated drug (Baron *et al.* 2011). The odontoblastic metalloproteinases in inflammatory conditions can explain partially this mechanism. The process of dentine matrix degradation and liberation of bisphosphonates by metalloproteinases can be similar in bone, although slower (Chaussain *et al.* 2013).

ZA infusion in peritonitis model leads to IL-1 $\beta$  overproduction (Norton *et al.* 2012). IL-1 is the most important cytokine described in gingival fluid and saliva of BRONJ (Bagan *et al.* 2013, Tsao *et al.* 2013). Furthermore, IL-1 $\beta$  is an important cytokine involved in pulpitis (Veerayutthwilai *et al.* 2007), and it was altered in this study. IL-1 $\beta$  can strongly active odontoblastic metalloproteinases (Hiyama *et al.* 2013) and augment bisphosphonate liberation in dental pulps raising IL-1 $\beta$  overexpression (included in nondental pulp cells as shown in this study) perpetuating this process.

Odontoblasts and nonodontoblast pulp cells respond by increasing pro-inflammatory cytokine synthesis, and caries can contribute to the rapid development of

pulpitis in patients who use bisphosphonates (Horst *et al.* 2011).

ZA infusion chronically has been associated with an increase in TNF- $\alpha$  (Cheung *et al.* 2011), IL-1 $\beta$  (Bonewald 2004, Tan *et al.* 2008) and high oxidative stress by iNOS activity (Almeida *et al.* 2010). High levels of these mediators modulate excessive apoptosis and act as a stimulus for the recruitment and activation of macrophages (Kogianni *et al.* 2008, Muratsu *et al.* 2013). Thus, ZA may contribute to an increase in these proinflammatory markers.

TNF- $\alpha$  and IL-1 $\beta$  are produced by NF- $\kappa$ B activation, but there was no difference in NF- $\kappa$ B levels. NF- $\kappa$ B is constitutively expressed in odontoblasts and is important for the production of collagen type I and dentine sialoproteins. Carious stimuli can modulate the immune response in odontoblasts, leading to overexpression of TNF- $\alpha$ , IL-1 $\beta$  and CCL20 (binder of CCR6; Veerayutthwilai *et al.* 2007), which participate in macrophage infiltration (Liu *et al.* 2014).

NF- $\kappa$ B activation is the primary driver of increased TNF- $\alpha$ , IL-1 $\beta$  and iNOS activity, but treatment with ZA did not alter NF- $\kappa$ B immunostaining. However, physiological expression of NF- $\kappa$ B in odontoblasts, accompanied by TNF- $\alpha$  and IL-1 $\beta$  overexpression, leads to pulp cell death (Hozhabri *et al.* 2015). In the pulp, there are complex ways to regulate these interactions, and other proteins can be involved in this process (ABCF1, FOS, IRF3, SP1, STA3, STAT1, FOXO, ERK1, TNFR and many others; Horst *et al.* 2011). Cytokine production in dental pulp tissue is increased in the presence of lipopolysaccharide (LPS), but a reduction in I $\kappa$ B- $\alpha$  activity, even in the presence of LPS, leads to an increase in TNF- $\alpha$ , IL-1 $\beta$  and IL-6 (Muratsu *et al.* 2013); thus, other mechanisms are responsible for this alteration in the dental pulp of rats treated with ZA.

ZA increased the expression of proinflammatory cytokines, independent from LPS. The addition of caries may further increase the production of these mediators, modifying the immune profile in the pulp and leading rapidly to an inflammatory disease with pulp damage and irreversible pulpitis and necrosis (ElSalhy *et al.* 2013).

Chemotherapies that alter the immune system can lead to odontalgia (Zadik *et al.* 2010), and it has been shown that high doses of ZA used chronically in chemotherapy protocols can modulate the immune response in dental pulps.

## Conclusion

ZA modified the immune cell profile in the dental pulp, increasing the number of macrophages and expression of pro-inflammatory markers (TNF- $\alpha$ , IL-1 $\beta$  and iNOS) independently of NF- $\kappa$ B immunostaining. This is the first study *in vivo* showing this relationship. However, more studies are needed to investigate the ways that ZA can increase cytokine expression in the dental pulp.

## Acknowledgements

This study was partially designed by and is dedicated to Professor Ronaldo Albuquerque Ribeiro (Laboratório de Farmacologia da Inflamação e do Câncer), who is no longer amongst us.

## Conflict of Interest

The authors have stated explicitly that there are no conflict of interests in connection with this article.

## References

- Accorsi-Mendonça T, Silva EJ, Marcaccini AM *et al.* (2013) Evaluation of gelatinases, tissue inhibitor of matrix metalloproteinase-2, and myeloperoxidase protein in healthy and inflamed human dental pulp tissue. *Journal of Endodontics* **39**, 879–82.
- Almeida M, Li H, Ambrogini E, Shoshana MB, Manolagas SC (2010) Oxidative stress stimulates apoptosis and activates NF- $\kappa$ B in osteoblastic cells via a PKC $\beta$ /p66shc signaling cascade: counter regulation by estrogens or androgens. *Molecular Endocrinology* **24**, 2030–7.
- Bagan J, Sheth CC, Soria JM *et al.* (2013) Bisphosphonates-related osteonecrosis of the jaws: a preliminary study of salivary interleukins. *Journal of Oral Pathology and Medicine* **42**, 405–8.
- Bakker AD, Silva VC, Krishnan R *et al.* (2009) Tumor necrosis factor alpha and interleukin-1beta modulate calcium and nitric oxide signaling in mechanically stimulated osteocytes. *Arthritis Rheumatism* **60**, 3336–45.
- Barasch A, Cunha-Cruz J, Curro FA *et al.* (2011) Risk factors for osteonecrosis of the jaws: a case-control study from the CONDOR dental PBRN. *Journal of Dental Research* **90**, 439–44.
- Baron R, Ferrari S, Russell RG (2011) Denosumab and bisphosphonates: different mechanisms of action and effects. *Bone* **48**, 677–92.
- Basso FG, Turrioni PS, Hebling J, de Souza Costa CA (2013) Effects of zoledronic acid on odontoblast-like cells. *Archives of Oral Biology* **58**, 467–73.
- Bonewald LF (2004) Osteocyte biology: its implications for osteoporosis. *Journal of Musculoskeletal and Neuronal Interactions* **4**, 101–4.
- Bruno KF, Silva JA, Silva TA, Batista AC, Alencar AHG, Estrela C (2010) Characterization of inflammatory cell infiltrate in human dental pulpitis. *International Endodontic Journal* **43**, 1013–21.
- Chaussain C, Boukpepsi T, Khaddam M, Tjaderhane L, George A, Menashi S (2013) Dentin matrix degradation by host matrix metalloproteinases: inhibition and clinical perspectives toward regeneration. *Frontiers in Physiology* **4**, 1–8.
- Cheung WY, Liu C, Tonelli-Zasarsky RM, Simmons CA, You L (2011) Osteocyte apoptosis is mechanically regulated and induces angiogenesis *in vitro*. *Journal of Orthopaedic Research* **29**, 523–30.
- Cvikl B, Agis H, Stögerer K, Moritz A, Watzek G, Gruber R (2011) The response of dental pulp-derived cells to zoledronate depends on the experimental model. *International Endodontic Journal* **44**, 33–40.
- Di Nardo Di Maio F, Lohinai Z, Darcangelo C *et al.* (2004) Nitric oxide synthase in healthy and inflamed human dental pulp. *Journal of Dental Research* **83**, 312–6.
- ElSalhy M, Azizieh F, Raghupathy R (2013) Cytokines as diagnostic markers of pulpal inflammation. *International Endodontic Journal* **46**, 573–80.
- Etemad-Moghadam S, Khalili M, Tirgary F, Alaeddini M (2009) Evaluation of myofibroblasts in oral epithelial dysplasia and squamous cell carcinoma. *Journal of Oral Pathology and Medicine* **38**, 639–43.
- Farges JC, Bellanger A, Ducret M *et al.* (2015) Human odontoblast-like cells produce nitric oxide with antibacterial activity upon TLR2 activation. *Frontiers in Physiology* **6**, 1–9.
- Harre U, Keppeler H, Ipseiz N *et al.* (2012) Moonlighting osteoclasts as undertakers of apoptotic cells. *Autoimmunity* **45**, 612–9.
- Hiraga T, Ninomiya T, Hosoya A, Nakamura H (2010) Administration of the Bisphosphonate Zoledronic Acid During Tooth Development Inhibits Tooth Eruption and Formation and Induces Dental Abnormalities in Rats. *Calcified Tissue International* **86**, 502–10.
- Hiyama T, Ozeki N, Mogi M *et al.* (2013) Matrix metalloproteinase-3 in odontoblastic cells derived from ips cells: unique proliferation response as odontoblastic cells derived from ES cells. *PLoS ONE* **8**, e83563.
- Horst OV, Horst JA, Samudrala R, Dale BA (2011) Caries induced cytokine network in the odontoblast layer of human teeth. *BMC Immunology* **12**, 9. doi:10.1186/1471-2172-12-9.
- Hozhabri NST, Benson MD, Vu MD *et al.* (2015) Decreasing NF- $\kappa$ B Expression Enhances Odontoblastic Differentiation and Collagen Expression in Dental Pulp Stem Cells Exposed to Inflammatory Cytokines. *PLoS ONE* **10**, e0113334.



- Huang GT, Potente AP, Kim JW, Zhang X (1999) Increased interleukin-8 expression in inflamed human dental pulps. *Oral Surgery, Oral Medicine, Oral Pathology, Oral Radiology, and Endodontology* **88**, 214–20.
- Iwasaki Y, Otsuka H, Yanagisawa N *et al.* (2011) In situ proliferation and differentiation of macrophages in dental pulp. *Cell Tissue Research* **346**, 99–109.
- Kamal MMA, Okiji T, Kawashima N, Suda H (1997) Defense responses of dentin/pulp complex to experimentally induced caries in rat molars: an immunohistochemical study on kinetics of pulpal la antigen-expressing cells and macrophages. *Journal of Endodontics* **23**, 115–20.
- Katz H (2005) Endodontic implications of bisphosphonate-associated osteonecrosis of the jaws: a report of three cases. *Journal of Endodontics* **31**, 831–4.
- Kogianni G, Mann V, Noble BS (2008) Apoptotic bodies convey activity capable of initiating osteoclastogenesis and localized bone destruction. *Journal of Bone and Mineral Research* **23**, 915–27.
- Kuiper JWP, Forster C, Sun C, Peel S, Glogauer M (2012) Zoledronate and pamidronate depress neutrophil functions and survival in mice. *British Journal of Pharmacology* **16**, 532–9.
- Liu L, Wang L, Wu Y, Peng B (2014) The expression of MCP-1 and CCR2 in induced rats periapical lesions. *Archives of Oral Biology* **59**, 492–9.
- Massa LF, Bradaschia-Correa V, Arana-Chavez VE (2006) Immunocytochemical study of amelogenin deposition during the early odontogenesis of molars in alendronate-treated newborn rats. *Journal of Histochemistry and Cytochemistry* **54**, 713–25.
- Misso G, Porru M, Stoppacciaro A *et al.* (2012) Evaluation of the in vitro and in vivo antiangiogenic effects of denosumab and zoledronic acid. *Cancer Biology and Therapy* **13**, 1491–500.
- Moinzadeh AT, Shemesh H, Neiryneck NA, Aubert C, Weselink PR (2013) Bisphosphonates and their clinical implications in endodontic therapy. *International Endodontic Journal* **46**, 391–8.
- Muratsu D, Yoshiga D, Taketomi T *et al.* (2013) Zoledronic acid enhances lipopolysaccharide-stimulated proinflammatory reactions through controlled expression of SOCS1 in macrophages. *PLoS ONE* **8**, e67906.
- Naidu A, Dechow PC, Spears R, Wright JM, Kessler HP, Opperman L (2008) The effects of bisphosphonates on osteoblasts in vitro. *Oral Surgery, Oral Medicine, Oral Pathology, Oral Radiology, and Endodontology* **106**, 5–13.
- Nishikawa S, Sasaki F (1999) Apoptosis of dental pulp cells and their elimination by macrophages and MHC class II-expressing dendritic cells. *Journal of Histochemistry and Cytochemistry* **47**, 303–11.
- Norton JT, Hayashi T, Brian C *et al.* (2012) Cutting Edge: nitrogen bisphosphonate-induced inflammation is dependent upon mast cells and IL-1. *Journal of Immunology* **188**, 2977–80.
- Ohazama A, Courtney JM, Sharpe PT (2003) Expression of TNF-receptor-associated factor genes in murine tooth development. *Gene Expression Patterns* **3**, 127–9.
- Oizumi T, Yamaguchi K, Funayama H *et al.* (2009) Necrotic actions of nitrogen-containing bisphosphonates and their inhibition by clodronate, a non-nitrogen-containing bisphosphonate in mice: potential for utilization of clodronate as a combination drug with a nitrogen-containing bisphosphonate. *Basic and Clinical Pharmacology and Toxicology* **104**, 384–92.
- Paula-Silva FWG, Ghosh A, La Silva B, Kapila YL (2009) TNF-alpha promotes an odontoblastic phenotype in dental pulp cells. *Journal of Dental Research* **88**, 339–44.
- Pezelj-ribaric S, Anic I, Brekalo I, Miletic I, Simunovic-Soskic M (2002) Detection of tumor necrosis factor  $\alpha$  in normal and inflamed human dental pulps. *Archives of Medical Research* **33**, 482–4.
- Rakian A, Yang WC, Gluhak-Heinrich J *et al.* (2013) Bone morphogenetic protein-2 gene controls tooth root development in coordination with formation of the periodontium. *International Journal of Oral Sciences* **5**, 75–84.
- Rossini M, Adami S, Viapiana O *et al.* (2012a) Long-term effects of amino-bisphosphonates on circulating  $\gamma\delta$  T cells. *Calcified Tissue International* **91**, 395–9.
- Rossini M, Adami S, Viapiana O *et al.* (2012b) Circulating  $\gamma\delta$  T cells and the risk of acute-phase response after zoledronic acid administration. *Journal of Bone and Mineral Research* **27**, 227–30.
- Rungvechvuttivittaya S, Okiji T, Suda H (1998) Responses of macrophage-associated antigen-expressing cells in the dental pulp of rat molars to experimental tooth replantation. *Archives of Oral Biology* **43**, 701–10.
- Scheller EL, Hankenson KD, Reuben JS, Krebsbach PH (2011) Zoledronic acid inhibits macrophage SOCS3 expression and enhances cytokine production. *Journal of Cellular Biochemistry* **112**, 3364–72.
- Scheper M, Badros A, Chaisuparat R, Cullen KJ, Meiller TF (2009) Effect of zoledronic acid on oral fibroblasts and epithelial cells: a potential mechanism of bisphosphonate-associated osteonecrosis. *British Journal of Haematology* **144**, 667–76.
- Silva PGB, Ferreira Junior AEC, Teófilo CR *et al.* (2015) Effect of different doses of zoledronic acid in establishing of bisphosphonate-related osteonecrosis. *Archives of Oral Biology* **60**, 1237–45.
- Silverman SL, Landesberg R (2009) Osteonecrosis of the jaw and the role of bisphosphonates: a critical review. *The American Journal of Medicine* **122**, S33–45.
- Tan SD, Bakker AD, Semeins CM, Kuijpers-Jagtman AM, Klein-Nulend J (2008) Inhibition of osteocyte apoptosis by fluid flow is mediated by nitric oxide. *Biochemical and Biophysical Research Communications* **369**, 1150–4.

- Tsao C, Darby I, Ebeling PR *et al.* (2013) Oral health risk factors for bisphosphonate-associated jaw osteonecrosis. *Journal of Oral and Maxillofacial Surgery* **71**, 1360–6.
- Veerayutthwilai O, Byers MR, Pham TT, Darveau RP, Dale BA (2007) Differential regulation of immune responses by odontoblasts. *Oral Microbiology and Immunology* **22**, 5–13.
- Welton JL, Morgan MP, Martí S *et al.* (2013) Monocytes and  $\gamma\delta$  T cells control the acute-phase response to intravenous zoledronate: insights from a phase IV safety trial. *Journal of Bone and Mineral Research* **28**, 464–71.
- Wigler R, Steinbock N, Berg T (2013) Oral cutaneous sinus tract, vertical root fracture, and bisphosphonate-related osteonecrosis: a case report. *Journal of Endodontics* **39**, 1088–90.
- Wolf AM, Tilg H, Gonsilius E (2006) The effect of zoledronic acid on the function and differentiation of myeloid cells. *Haematologica* **91**, 1165–71.
- Zadik Y, Vainstein V, Heling I, Neuman T, Drucker S, Elad S (2010) Cytotoxic chemotherapy-induced odontalgia: a differential diagnosis for dental pain. *Journal of Endodontics* **36**, 1588–92.