

Indian J Med Res 141, March 2015, pp 340-342

## Use of maggot therapy for treating a diabetic foot ulcer colonized by multidrug resistant bacteria in Brazil

Marilia A.R.Q. Pinheiro<sup>3</sup>, Julianny B. Ferraz<sup>2</sup>, Miguel A.A. Junior<sup>1</sup>, Andrew D. Moura<sup>4</sup>, Maria E.S.M. da Costa<sup>1</sup>, Fagner J.M.D. Costa<sup>1</sup>, Valter F.A. Neto<sup>4</sup>, Renato M. Neto<sup>1</sup> & Renata A. Gama<sup>3</sup>

<sup>1</sup>Laboratory of Mycobacteria, Department of Microbiology and Parasitology, Biosciences Center, Federal University of Rio Grande do Norte. <sup>2</sup>Surgical Clinic Department, Committee of the Curative Infirmary University, Hospital Onofre Lopes, Federal University of Rio Grande do Norte, <sup>3</sup>Laboratory of insect & Vectors, Department of Microbiology & Parasitology, Biosciences Center, Federal University of Rio Grande do Norte, & <sup>4</sup>Laboratory of Malaria and Toxoplasmosis, Department of Microbiology & Parasitology, Biosciences Center, Federal University of Rio Grande do Norte, Natal/RN, Brazil

Received October 11, 2013

**This study reports the efficacy of maggot therapy in the treatment of diabetic foot ulcer infected with multidrug resistant microorganisms. A 74 year old female patient with diabetes for over 30 years, was treated with maggot therapy using larvae of *Chrysomya megacephala*. The microbiological samples were collected to evaluate aetiology of the infection. The therapy done for 43 days resulted in a reduction of necrosis and the ulcer's retraction of 0.7 cm<sup>2</sup> in area. Analysis of the bacteriological swabs revealed the presence of *Escherichia coli*, *Klebsiella pneumoniae* and *Pseudomonas aeruginosa*. Further studies need to be done to confirm the role of maggot therapy in wound healing using a large sample and a proper study design.**

**Key words** *Chrysomya megacephala* - diabetic foot ulcer - *Klebsiella pneumoniae* - *Pseudomonas aeruginosa*

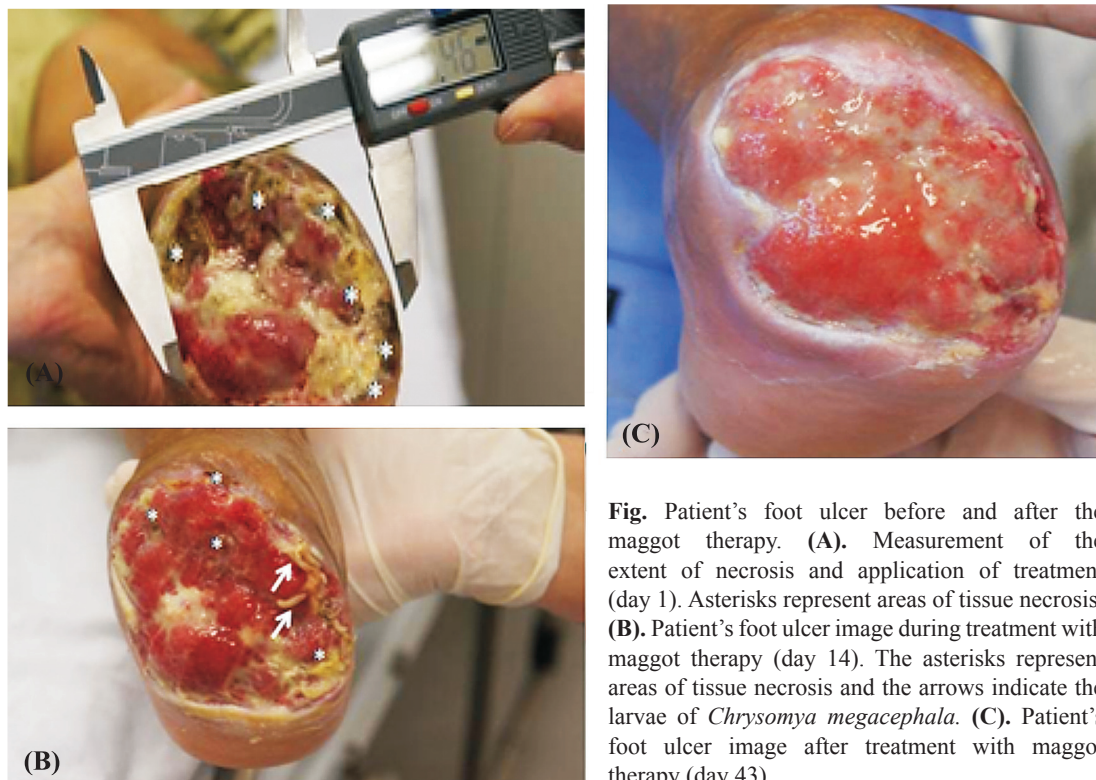
Maggot therapy is known to be used in chronic wounds to remove necrotic tissue, stimulate granulation tissue formation and kill bacteria<sup>1,2</sup>. In diabetic foot ulcers with the problem of bacterial resistance, this therapy has been used as an alternative treatment of these ulcers. We report here a case study in Brazil using maggot therapy for treating chronic ulcers infected with multidrug-resistant bacteria in a diabetic patient.

A 74 year old female patient having diabetes for over 30 years, reported to the Surgical Clinic Department, University Hospital Onofre Lopes (HUOL)- University Federal do Rio Grande do Norte, Brazil, with a foot ulcer in August 2012. The second instar larvae of the *Chrysomya megacephala* (Diptera: *Calliphoridae*) were used in this study for maggot therapy and the maintenance and eggs disinfection processes were performed using procedures recommended

by Marcondes<sup>3</sup>. The larvae were obtained from established colonies in the insectory of Laboratory of Insect and Vectors, Department of Microbiology and Parasitology, Biosciences Center, Federal University of Rio Grande do Norte. The larvae were removed from the medium, washed with sterile water and transferred to a sterile container. The technique of maggot therapy consisted of an initial wash with saturated sodium chloride followed by collection of clinical specimens for microbiological analysis and application of the free-range larvae (5 per cm<sup>2</sup> of tissue compromised) directly at the ulcer. The clinical specimen was sent in Stuart transport medium (Difco Laboratories, USA) to Mycobacteria Laboratory, department of Microbiology and Parasitology, Federal University of Rio Grande do Norte. The processing of clinical specimens was performed using procedures and culture media recommended by Murray *et al*<sup>4</sup>. Biochemical tests were performed for bacteria identification at species level. To perform the antimicrobial sensibility test (AST), the Kirby-Bauer's agar disk diffusion method was used<sup>5</sup>. The bacterial strains that showed the multidrug resistance pattern were subjected to genotypic analysis to confirm the presence of genes encoding TEM, SHV, and CTX-M<sup>6</sup>. Strains of *Escherichia coli* (ATCC

25922) and *Klebsiella pneumoniae* (ATCC 700603) were included as controls.

The study was approved by the ethics committee of the Federal University of Rio Grande do Norte, Brazil. Six biological dressings were done with an interval of every 48 h. Before therapy, an extension of tissue impairment of 8.4 cm<sup>2</sup> was obtained (Fig. A) and after two weeks of treatment (14 days) a retraction of the ulcer 0.7 cm<sup>2</sup> was observed (Fig. B). At the end of treatment (43 days) the ulcer's surface area was occupied by granulation tissue (Fig. C). The maggot therapy was found to be an effective and inexpensive method of debridement, providing a rapid acceleration in the process of wound healing<sup>7,8</sup>. Importantly, the effect of using the debridement maggot therapy occurs not only by the physical activity of larvae (by their mandibles) but also by secretions and excretions such as trypsin, collagenase, and chymotrypsin, showing that the lytic activity is able to promote the dissolution of necrotic tissue. This therapy also eliminated multidrug resistant microorganisms (*K. pneumoniae*, *E. coli*, *Pseudomonas aeruginosa*) present in the wound, as reported earlier<sup>9</sup>. The SHV and CTX-M genotypes were observed only in the *K. pneumoniae* isolates. These results indicated the



**Fig.** Patient's foot ulcer before and after the maggot therapy. **(A)**, Measurement of the extent of necrosis and application of treatment (day 1). Asterisks represent areas of tissue necrosis. **(B)**, Patient's foot ulcer image during treatment with maggot therapy (day 14). The asterisks represent areas of tissue necrosis and the arrows indicate the larvae of *Chrysomya megacephala*. **(C)**, Patient's foot ulcer image after treatment with maggot therapy (day 43).

presence of ESBL (extended-spectrum beta-lactamase) in bacteria. Bexfield *et al*<sup>10</sup> demonstrated the efficacy of these compounds against strains of methicillin-resistant *Staphylococcus aureus* and other bacteria. Several peptides produced in whole body extract of maggots with high antimicrobial activity as well as compounds present in their haemolymph have been shown to have activity against *P. aeruginosa*<sup>11</sup>.

In conclusion, considering the role of maggot therapy in wound healing, particularly in diabetic ulcer and its low cost compared with the other usual treatments, there is a need to evaluate its safety and efficacy on a large number of patients.

### References

1. Martini RK, Sherman RA. Maggot debridement therapy. *J Bras Med* 2003; 85 : 82-5.
2. Sherman RA, Hall MJR, Thomas S. Medicinal Maggots: an ancient remedy for some contemporary afflictions. *Annu Rev Entomol* 2000; 45 : 55-81.
3. Marcondes CB. *Use of maggot therapy for treating a diabetic foot ulcer colonized by multidrug resistant bacteria in Brazil*. 1<sup>st</sup> ed, Florianópolis: Editora da UFSC; 2006.
4. Murray PR, Baron EJ, Pfaller MA, Tenover FC, Tenover RH. *Manual of clinical microbiology*. 7<sup>th</sup> ed. Washington DC: ASM Press; 1999.
5. Clinical and Laboratory Standards Institute (CLSI). *Performance standards for antimicrobial susceptibility testing*; 23<sup>rd</sup> informational supplement. Wayne, PA, USA: CLSI; 2013.
6. de Oliveira CF, Salla A, Lara VM, Rieger A, Horta JA, Alves SH. Prevalence of extended spectrum beta-lactamases producing microorganisms in nosocomial patients and molecular characterization of the shv type isolates. *Braj J Microbiol* 2010; 41 : 278-82.
7. Tanyuksel M, Araz E, Dundar K, Uzun G, Gumus T, Alten B, *et al*. Maggot debridement therapy in the treatment of chronic wounds in a military hospital setup in Turkey. *Dermatology* 2005; 210 : 115-8.
8. Chambers L, Woodrow S, Brown AP, Harris PD, Philips D, Hall M, *et al*. Degradation extracellular matrix components by defined proteinases from the green bottle larva *Lucilia sericata* used for the clinical debridement of non-healing wounds. *Br J Dermatol* 2003; 148 : 14-23.
9. McInnes W, Ruzehaji N, Wright N, Cowin AJ, Fitridge R. Venous ulceration contaminated by multi-resistant organisms: larval therapy & debridement. *J Wound Care* 2013; 22 (Suppl 10): s27-30.
10. Bexfield A, Nigam Y, Thomas S, Ratcliffe NA. Detection and partial characterization of two antibacterial factors from the excretions/secretions of the medicinal maggot *Lucilia sericata* and their activity against methicillin-resistant *Staphylococcus aureus* (MRSA). *Microbes Infect* 2004; 6 : 1297-304.
11. Huberman L, Gollop N, Mumcuoglu KY, Block C, Galun R. Antibacterial properties of whole body extracts and haemolymph of *Lucilia sericata* maggots. *J Wound Care* 2007; 16 : 123-7.

*Reprint requests:* Dr Renato Motta Neto, Department of Microbiology & Parasitology, Biosciences Center, Federal University of Rio Grande Do Norte, Av. Senador Salgado Filho, 3000, Candelaria, Natal, RN, Brasil  
e-mail: [renato@cb.ufrn.br](mailto:renato@cb.ufrn.br)