

Aneurysmal Bone Cyst of the Zygomatic Arch Causing Limited Mouth Opening

CASE REPORT

Breno Souza Benevides¹, José Maria Sampaio Menezes Junior²,
Marcelo Esmeraldo Holanda³, Fabrício Bitu Sousa⁴, Mariana Canuto Melo de Sousa Lopes⁴,
Cauby Maia Chaves Junior⁵, Hermes Melo Teixeira Batista⁶, Bruno Souza Benevides⁷

Abstract

The Aneurysmal Bone Cyst (ABC) is an expansive osteolytic, radio-lucent, multilocular, eccentric lesion of unknown origin consisting of spaces filled with blood in any segment of the skeleton, being most frequently encountered in the diaphysis of the long bones or the spinal cord. It may occur as distinct clinico-pathological entity or as pathophysiological alteration of a preexisting lesion, like giant-cells lesion, fibrous dysplasia, ossifying fibroma, osteoblastoma, epiphysary chondroblastoma and even malignant lesions such as osteosarcoma. This paper reports a rare case of ABC in the zygomatic arch of a young female patient who presented facial asymmetry and progressive limitation in mouth opening, treated by resective surgical procedure and discusses the clinical, radiological and histological features of this pathology along with its treatment.

- 1 Oral and Maxillofacial Surgeon. Hospital Batista Memorial. Fortaleza-CE, Brazil.
- 2 Oral and Maxillofacial Surgeon. Santa Casa de Misericórdia Hospital. Fortaleza-CE, Brazil.
- 3 Head and Neck Surgeon. Hospital Santa. Casa de Misericórdia. Fortaleza-CE, Brazil
- 4 Oral Pathologist to Oral Pathology.
- 5 Orthodontics. Universidade Federal do Ceará. Fortaleza-CE, Brazil.
- 6 De Laboratory of Design and Scientific Writing. Community Health Department, Faculdade de Medicina do ABC. Santo André-SP, Brazil.
- 7 Family Physician. UECE - Universidade Estadual do Ceará. Doctorate in Collective Health. 1700 Dr. Silas Munguba Av. Fortaleza, CE, Brazil.

Contact information:

✉ brenosbenevides@gmail.com

Keywords

Bone cysts, aneurysmal, zygoma

Introduction

Aneurysmal Bone Cyst (ABC) is a clinicopathological entity described in the literature [1], which etiology and etiopathogenesis are unknown. There is also controversy about its nomenclature, because this lesion is not a vascular aneurysm and also not an osseous cystic lesion [2]. The histological findings reveal giant cells surrounded by a fibrous connective tissue, varied amounts of bone and reactional osteoid tissue, numerous cavities or blood sinusoids without epithelial or endothelial coating [3, 4].

ABC commonly affects the metaphyseal region of long bones, pelvis or vertebral column. It presents as an eccentric tumor that insufflates the cortical bone and by its growth destroys the metaphyseal-epiphyseal region. ABC occurs more commonly in females in their second-decade [5]. Only 2% of all ABC literature related cases are on the head and neck region [6] and represent 1.5% of all non-odontogenic cysts of jaws [7]. In these cases, mandible is the most affected bone, followed by maxilla (3:1). Zygomatic bone is rarely involved [3, 4]. The radiological findings of this lesion are not unique and, therefore, not pathognomonic [4].

Clinical evolution of ABC varies from a lesion showing self-limited slow-growth pattern to an aggressive lesion showing rapid destructive behavior, such as the malignant neoplastic tumors [8]. Treatment of choice is complete surgical removal. This may be difficult in cases of extensive multiloculated lesions. Therefore, some treatment alternatives were proposed: lesional resection with or without bone grafting, curettage with or without cryotherapy or bone grafting, arterial embolization followed by surgical excision [9]. Intralesional corticosteroid, calcitonin injection or radiotherapy (RT) can be used as a unique treatment or as an adjuvant treatment (10). Whenever recurrence is present, it is due to inadequate removal of the lesion approach and/or incomplete resection [3, 4].

Case report

A 14 year-old female patient was referred to dental care due to progressively growing hard asymptomatic swelling on the face in the middle third region. The patient also had a progressively decreasing mouth opening for the past 5 months (figures 1 and 2).

Clinical examination revealed facial asymmetry and local swelling of the left zygomatic arch, normal overlying skin and 32mm interincisal mouth opening. Computed Tomography (CT) showed an expansive hypodense lesion of 4cm x 2cm in size

Figure 1: Preoperative frontal view of the patient at the age of 14 with a swallow of the left side third middle face.

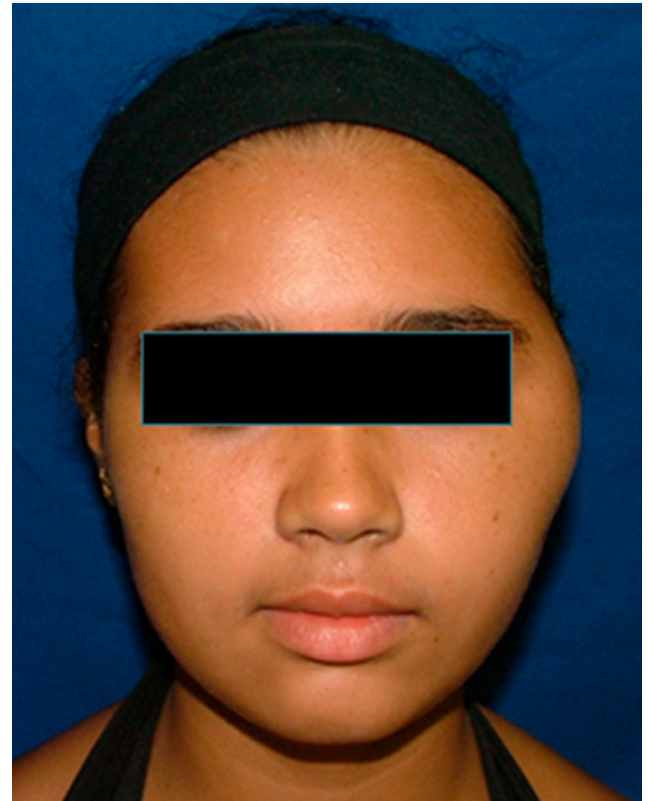
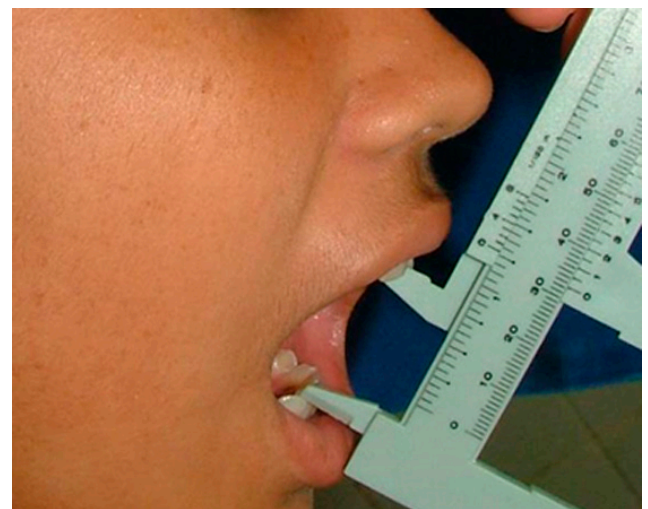
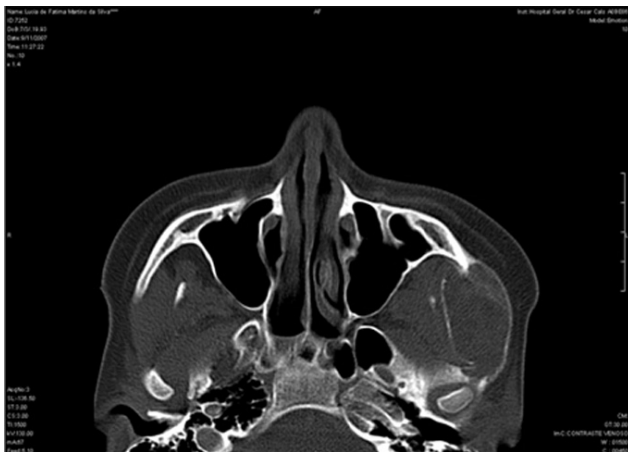Figure 2: Preoperative view, showing a 32mm limited mouth opening.



with a discontinuous hyperdense lining and discrete hyperdense loculation in its interior (**figure 3**). This lesion expanded the entire left zygomatic arch and showed a close anatomic relationship to the ipsilateral coronoid process of the mandible, which was probably the etiologic factor for the progressive limited mouth opening. The laboratory exams revealed normal blood concentrations of

Figure 3: CT hypodense expansive lesion involving the left zygomatic arch with hyperdense lining.



Parathormone, Calcium and Alkaline Phosphatase, which suggested a normal physiologic bone metabolism pattern. An incisional biopsy procedure was performed and the histopathological findings were consistent with ABC.

Definitive surgical treatment was performed through preauricular approach with superior and anterior extension (**figure 4**). Final histological examination revealed blood collections surrounded by connective tissue lining, which showed giant multinucleated cells along with reactive bone formation, conclusive of ABC (**figure 5**). Clinical postoperative examination after 30 days showed facial symmetry, minimal scar and a 40mm mouth opening. CT scan revealed complete removal of the lesion in the left zygomatic arch.

The patient is under regular follow-up and two years after the procedure. There is no clinical evi-

dence of recurrence. Facial CT scans were taken regularly in periods of 6 months and there is also no radiological evidence of recurrence. Normal range of mouth opening, facial contour and fa-

Figure 4: Intraoperative view. The lesion was exposed and resected through pre-auricular approach with antero-superior extension.

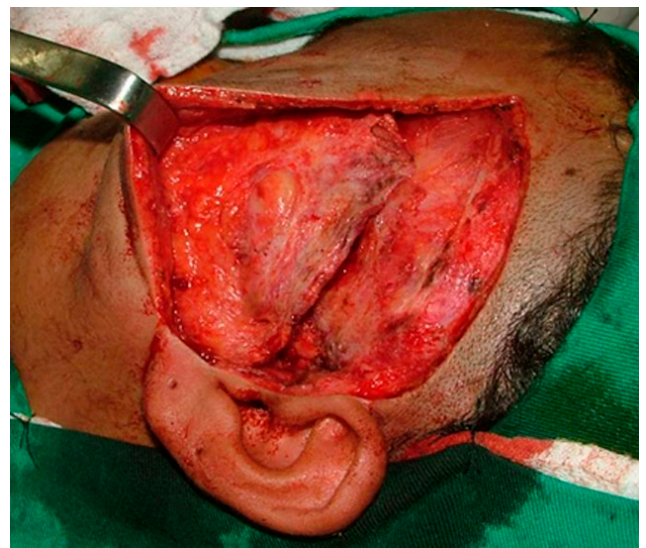
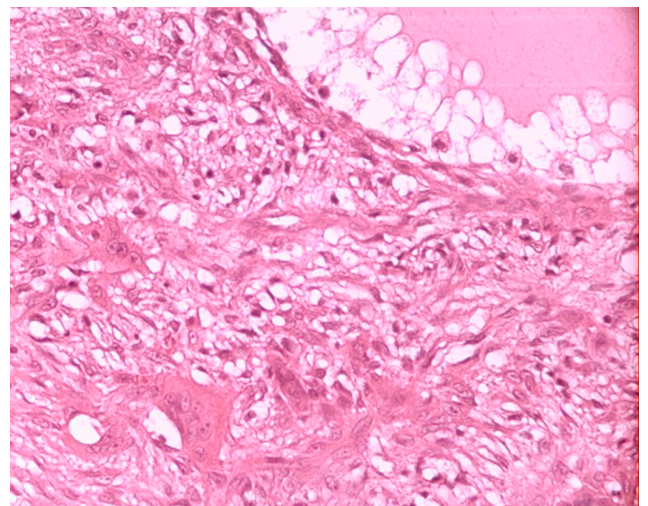


Figure 5: 400 X HE. Periphery of a cavity filled with blood that realize multinucleated giant osteoclast-like cells involved into a fibrous stroma consisting of fibroblast-like spindle mononuclear cells.



mandibular ascending ramus, followed by maxilla. The commitment of other bones of the head and neck is considered rare, specially the zygomatic arch [9, 14, 15].

Clinically ABC manifests as swelling of firm consistency, progressive and expansile with associated pain. When in the maxilla or mandible, the change of occlusion and tooth displacement are common clinical findings. Limitation of mouth opening as a result of mechanical impaction bone, as described here, is not a rare clinical finding [7]. Its biological behavior is variable, however, often shows rapid growth and local aggressiveness [5]. Diffuse aggressiveness with rapid destruction of adjacent tissues and structures and involvement of vital structures is a rare finding [8, 9] In our case, the lesion was limited to the bony anatomy, without the involvement of important structures and showed no evidence of local aggressiveness.

ABC radiographically presents as a radiolucent unicystic, uni or multilocular lesion with soap bubble or honeycomb appearance. It causes expansion, perforation or destruction of cortical bone and may show periosteal reaction with reactionary bony formation and peripheral sclerotic bone formation [3]. Differential diagnosis includes ameloblastoma, myxoma, central giant-cell lesion, hyperparathyroidism brown tumor, odontogenic cysts and bone venous malformation [16]. CT and Magnetic Resonance Imaging (MRI) enable the delineation of the margins of the lesion and its septa, as well as association with adjacent structures [3, 4, 6]. MRI can also be useful to assess if there is any perilesional edema or extraosseous soft tissue spread [6].

Histopathological analysis of a tissue sample exhibits microscopic blood-filled cavities, circumscribed by fibrous connective tissue, consisting of spindle-shaped "fibroblast-like" and giant "osteoclast-like" multinucleated cells, plus reactionary bone or irregular osteoid [17, 18]. Our findings were similar.

Several treatment modalities have been proposed for the ABC. These include monitoring and long-term observation which resulted in involution of lesion [19], percutaneous fibrosant agent injections [20], intra-lesional injections of calcitonin, which has inhibitory effect on osteoclastic activity and osteoinductive properties, in combination with corticosteroid injections that has angiostatic and inhibitory effect on fibroblasts. However, this treatment generally lasts for a long period of time marked with multiple repetitions of injections and has unpredictable results [21]. Cryotherapy and RT were also reported and used as an adjunct to surgical curettage to reduce the recurrence rate. However, although RT has been shown as an effective treatment modality for the ABC, it was abandoned due to its high potential for sarcomatous degeneration [22].

The ablative surgery is the most described. The length of the procedure depends on the size and location of the lesion. Reports of curettage and bone grafting are also found, however are associated with high recurrence rates and present with risks of massive intraoperative bleeding [3]. Embolization prior to surgical manipulation is a mean to prevent bleeding and interferes with the course of the injury, since it promotes regression of soft tissue, sclerosis and reactive bone formation [9, 23]. In this case, embolization was not done as image revealed that there was no vascular involvement or major nutrient artery involving the tumor.

Complete resection is the surgical treatment modality that is considered more effective and associated with least recurrence [3, 7, 10, 15, 16]. Some authors feel that this radical surgical excision should be restricted to extensive lesions that occupy the affected bone totally and to recurrent lesions due to the severe morbidity of the procedure [20, 24]. The choice of resective surgical approach for this case was based on the wide extent of the lesion and the total involvement of the left zygomatic arch. Furthermore, it is known that the recurrence rate

is directly related to previous incomplete resection and simple curettage may result in recurrence in 50 % of cases [5]. The type of surgical access performed is related to fewer complications and reduced morbidity [25].

Despite there are different types of treatment for the ABC, there is a tendency to choose the total resection with a safety margin that allows proper treatment and reduces the chance of recurrence. Thus, surgical resection proved to be a viable treatment alternative, once the patient is in the postoperative period of two years and there is no clinical or imaginological evidence of recurrence and the functionality of the stomatognathic system is maintained.

References

1. Jaffe HL, Lichtenstein L. Solitary unicameral bone cyst with emphasis on the roentgen picture: the pathologic appearance and the pathogenesis. *Arch Surg* 1942; 44:1004.
2. Boyd RC. Aneurysmal bone cysts of the jaws. *Br Oral Surg* 1978-1979; 16:248.
3. Struthers PJ, Shear M. Aneurysmal bone cysts of the jaws (II) pathogenesis. *Int J Oral Surg* 1984; 13:92.
4. Shafer WG, Hine MK, Levy BM. *A Textbook of Oral Pathology*. 4th ed. Philadelphia: WB Saunders; 1983.
5. Lichtenstein L. Aneurysmal bone cyst: observations on fifty cases. *Am J Bone Joint Surg* 1957; 39:873-882.
6. Lerant G, Ivanyi E, Toth E, Levai A, Godeny M. Aneurysmal bone cyst of the zygomatic arch: a case report. *Clin Imaging* 2013; 37(5):957-61.
7. Motamedi MH, Yazdi E. Aneurysmal bone cysts of the jaws: Analysis of 11 cases. *J Oral Maxillofac Surg* 1994; 52:471-475.
8. Hardee OS, Whear NM, Morgan PR. Aneurysmal bone cyst of the maxilla - an association with tooth resorption. *J Craniomaxillofac Surg* 1992; 20:266-269.
9. Page EL, Glenn EP. Aneurysmal bone cyst of the zygomatic arch. *Head & Neck* 1994; 594-597.
10. Kumar VV, Malik NA, Kumar DB. Treatment of large recurrent aneurysmal bone cysts of mandible: transosseous intralesional embolization as an adjunct to resection. *Int J Oral Maxillofac Surg* 2009; 38:671-676.
11. Levy WM, Miller AS, Bonakdarpour A, Aegerter E. Aneurysmal bone cyst secondary to other osseous lesions. Report of 57 cases. *Am J Clin Pathol* 1975; 63:1-8.
12. Tai YT, Yen PC, Chou EK. Aneurysm bone cyst presented as a zygomatic mass after facial trauma. *J Trauma* 2011; 70(4):E74.
13. Althof PA, Ohmori K, Zhou M, Bailey JM, Bridge RS, Nelson M, Neff JR, Bridge JA. Cytogenetic and molecular cytogenetic findings in 43 aneurysmal bone cysts: aberrations of 17p mapped to 17p13.2 by fluorescence in situ hybridization. *Mod Pathol* 2004; 17: 518-525.
14. Winters V, Schraepen T, Geusens E, Vanwijck R, Broeckx. Aneurysmal bone cyst of the zygomatic arch. *J Belge Radiol* 1998; 81(1):7-8.
15. Eveson JW, Moos KF, MacDonald DG. Aneurysmal bone cyst of the zygomatic arch. *Br J Oral Surg* 1978; 15(3):259-64.
16. Kiattavorncharoen S, Joos U, Brinkschmidt C, Werkmeister R. Aneurysmal bone cyst of the mandible: a case report. *Int J Oral Maxillofac Surg* 2003; 32:419-422.
17. Jundt G. Aneurysmal Bone Cyst. In: *World Health Organization Classification of Tumours Pathology and Genetics os Head and Neck Tumours*. Barnes L (Editor). Lyon: IARC Press; 20005. p326.
18. Ettl T, Stander S, Schwartz S, Reichert TE, Driemel O. Recurrent aneurysmal bone cyst of the mandibular condyle with soft tissue extension. *Int J Oral Maxillofac Surg* 2009; 38:6.

19. Hernandez GA, Castro A, Castro G, Amador E. Aneurysmal bone cyst versus hemangioma of the mandible. Report of a long-term follow-up of a self-limiting case. *Oral Surg Oral Med Oral Pathol* 1973; 76:790-796.
20. Adamsbaum C, Mascard E, Guinebre-Tiere JM, Kalifa G, Dubousset J. Intra-lesional Ethibloc injection in primary aneurysmal bone cysts: an efficient and safe treatment. *Skeletal Radiology* 2003; 32: 559-566.
21. Gladden Jr. ML, Gillingham BL, Hennrikus W. Aneurysmal bone cyst of the first cervical vertebrae in a child treated with percutaneous intralesional injection of calcitonin and methylprednisolone. A case report. *Spine* 2000; 25:527-530.
22. Rapidis AD, Vallianatou D, Apostolidis C, Lagogiannis G. Large lytic lesion of the ascending ramus, the condyle and the infratemporal region. *J Oral Maxillofac Surg* 2004; 62:996-1001.
23. Cory DA, Fritsch AS, Cohen MD, Mail JT, Holden RW, Scott JÁ, De Rosa GP. Aneurysmal bone cysts: imaging findings and embolotherapy. *Am J Roentgenol* 1989; 153:369-373.
24. Campanacci M, Capanna R, Picci P. Unicameral and aneurysmal bone cysts. *Clin Orthop* 1986; 204:25-36.
25. Al-Kayat A, Bramley PA. A modified pre-auricular approach to the temporomandibular joint and malar arch. *Br J Oral Maxillofac Surg* 1979; 17:91.

Comment on this article:

<http://medicalia.org/>

Where Doctors exchange clinical experiences, review their cases and share clinical knowledge. You can also access lots of medical publications for free. **Join Now!**

Publish with iMedPub

<http://www.imed.pub>

International Archives of Medicine is an open access journal publishing articles encompassing all aspects of medical science and clinical practice. IAM is considered a megajournal with independent sections on all areas of medicine. IAM is a really international journal with authors and board members from all around the world. The journal is widely indexed and classified Q1 in category Medicine.