

Cleft Lip/Palate Reconstruction Using Techniques from Abbé and Von Langenbeck

CASE REPORT

Romildo José de Siqueira Bringel^{1,2}, Ivo Cavalcante Pita Neto^{1,2},
Jéferson Martins Pereira Lucena Franco¹, Júlio Leite de Araújo Junior¹, Maria Socorro Ferreira¹,
Daniela Neves Bringel³, David Gomes de Alencar Gondim¹,
Fernando Bastos Pereira Júnior⁴, Luciano Miller Reis Rodrigues²

Abstract

Cleft lip and cleft palate are congenital deformities of embryonic origin that are formed between the 8th and the 32nd week of gestation, are caused by a failure of fusion of the median nasal processes. They are considered to be the most common congenital deformities among humans, originated in pharyngeal or brachial apparatus and its derivatives. Clinically and socially disabled individuals with cleft lip or cleft palate present problems of eating, swallowing, dysarthria, hypoplasia of the maxilla during growth, occlusal disharmony, low self-esteem and external appearances in different degrees. This article aims to present a clinical case of cleft lip/palate in adult, proceeding with its surgical correction by applying the techniques of Abbé and Von Langenbeck, emphasizing the importance of a correct diagnosis and proper treatment.

- 1 School of Dentistry, Faculdade Leão Sampaio, Juazeiro do Norte, CE, Brazil.
- 2 Laboratory of Study Design and Scientific Writing, Faculdade de Medicina do ABC, Santo André, SP, Brazil.
- 3 School of Medicine, Universidade Federal do Ceará, Fortaleza, CE, Brazil.
- 4 Department of Health of the State University of Feira of Santana, Feira de Santana, BA, Brazil.

Contact information:

Romildo José de Siqueira Bringel.

✉ romildobringel@hotmail.com

Keywords

Cleft Lip; Cleft Palate; Lip Reconstruction; Epidemiology.

Introduction

Cleft lip and cleft palate are congenital deformities of embryonic origin that are formed between the 8th and the 32nd week of gestation, are caused by a failure of fusion of the median nasal processes. They are considered to be the most common congenital deformities among humans, originated in pharyngeal or brachial apparatus and its derivatives. (FARRONATO, *et al.*, 2014; MONROY, *et al.*, 2012).

The prevalence varies considerably according to geographic region, race, gender, ethnic group, maternal habits, socioeconomic condition, heredity, paternal and maternal age, being found between 1.4/1000 Chinese and 3.6/1000 Americans. Worldwide it is estimated that each 600-700/1 born with cleft lip and palate. The cracks present interesting racial predilection, occur less often in blacks and are more common in the Eastern, showing greater propensity among men than women, in the proportion of 3/2. (KUHN, *et al.*, 2012; RIBEIRO, *et al.*, 2005; SILVA, *et al.*, 2002).

In 1972, SPINA *et al.* proposed a classification based on the incisive foramen, boundary between the primary and the secondary palate, separating the cracks in 4 types: Pre-incisive foramen fissures (lip and alveolar arcade), that may be unilateral or bilateral, incomplete or complete; Post-incisive foramen fissures (hard palate and soft palate), that may be incomplete or complete; Trans-incisive foramen fissures (lip, alveolar arcade, hard and soft palate), that may be bilateral or unilateral; and rare facial fissures, which include other cracks in the face in addition of lip and palate. (SPINA, *et al.*, 1972; RIBEIRO, *et al.*, 2005; ALONSO, *et al.*, 2010).

Patients with orofacial clefts present, during development of the jaws, great possibilities of morphometric deficit with transverse and anteroposterior atresias, causing bad occlusion and maintaining dental inclusions. (FERREIRA, *et al.*, 2004; REIS, *et al.*, 2006; PITA-NETO, *et al.*, 2015).

The treatment starts shortly after birth and extends into adulthood, and its goal is the aesthetic and functional rehabilitation aimed at repairing the Stomatognathic system. Early surgical repair is of fundamental importance for the prevention of the Cranio-maxillofacial growth, development of speech and proper dental outburst, requiring multidisciplinary teams for the resolution of cases of cleft lip and palate. (FARRONATO, *et al.*, 2014; KIM, *et al.*, 2015)

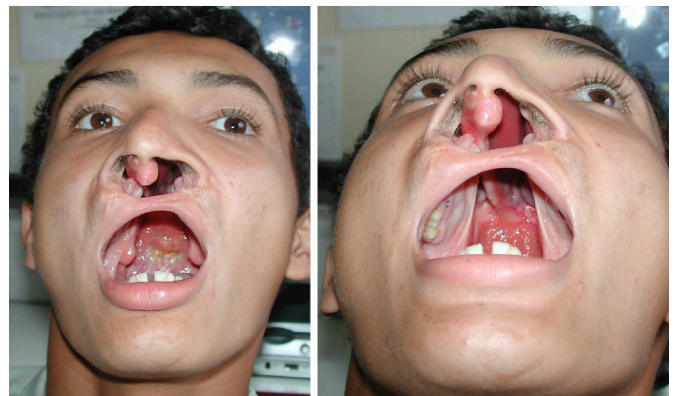This article aims to present a clinical case of cleft lip/palate in adult, proceeding with its surgical co-

rection by applying the techniques of Abbé and Von Langenbeck, emphasizing the importance of a correct diagnosis and proper treatment.

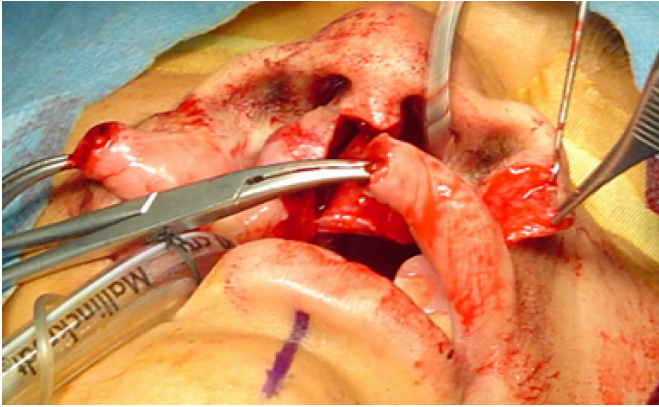
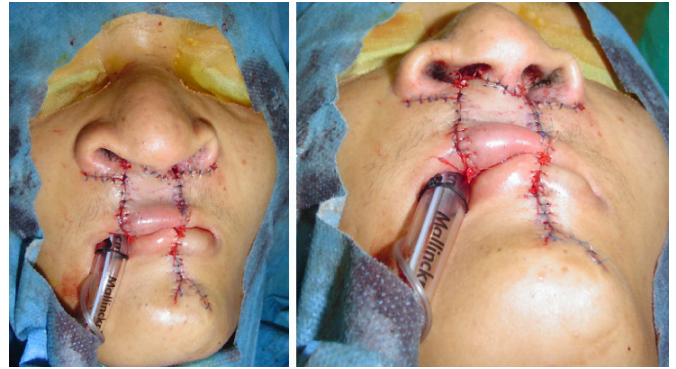
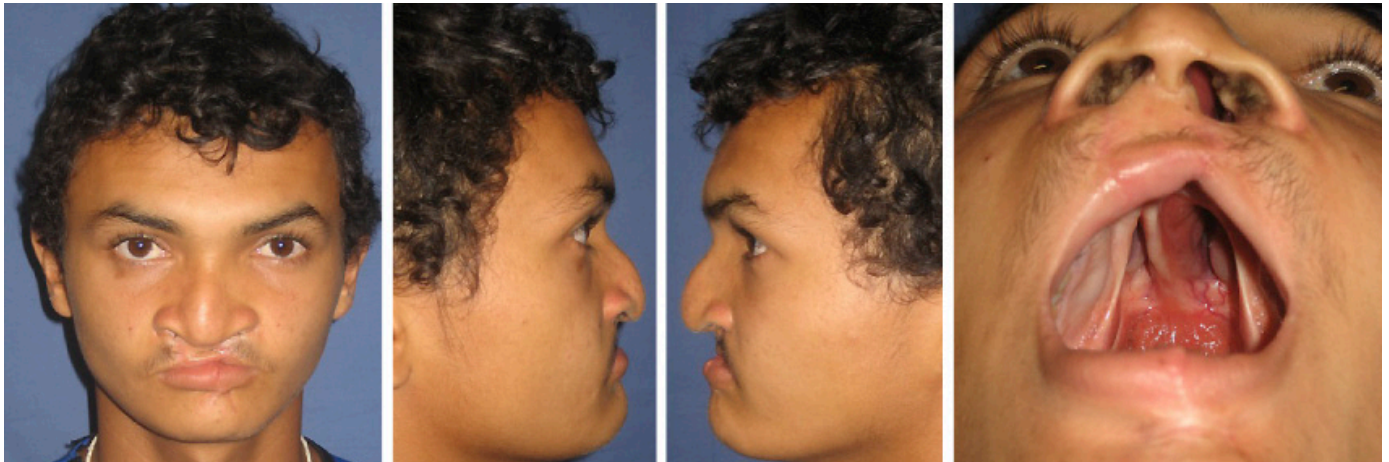Clinical case

Patient W.S.S, feoderm, 22 years old, male, attend the Oral and Maxillofacial Surgery and Traumatology service of Hospital and Maternity São Vicente de Paula (HMSVP) in Barbalha-CE, Brazil, reporting complaints of dysphonia, dysphagia, otitis, halitosis, foul odor and low self esteem. Clinical examination showed that he had general normal health standards, with facial deformity as a result of the trans-incisive foramen bilateral fissure, according to the classification of Spina, and also important commitment of the nose (collapse of the nasal wings, enlargement of the cross-section of the nostrils, nose asymmetry, columella retraction, deviation from the caudal portion of the nasal septum, middle and posterior segment deviation of nasal septum and nasal floor missing). Intraoral examination showed alveolar edge, hard palate and soft palate bilaterally compromised by the fissure (**Figure 1**). It was noticed localized dental absences and dental remnants in poor condition.

Figure 1: Facial aspect showing trans-incisive foramen bilateral fissure.



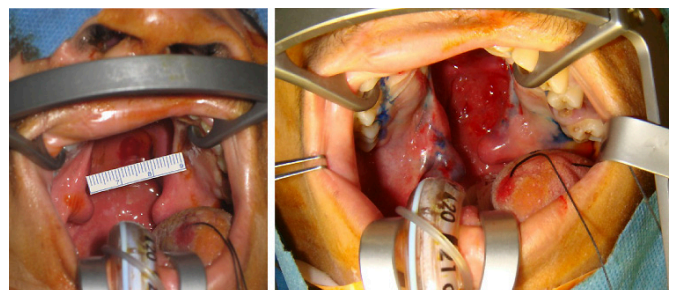
With the clinical findings, it was proposed the implementation of tongue septorhinoplasty for correction of nasolabial fissure using the technique

Figure 2: Transoperative aspect.**Figure 3:** Immediate postoperative. Observing the harmony of the cupid arc.**Figure 4:** Clinical aspect a year after tongue septorhinoplasty with bilateral palatin crack.

of Abbé, under general anesthesia and orotracheal intubation. Initially the demarcation of the midline of the lower lip was made with ipsilateral distance in vermilion for filtral treatment of 8 mm. The marking was idealized taking into account the longitudinal size, to correlate the distance of pro-lip. The incision was performed in order to release the total plans, including skin, subcutaneous tissue, muscle, and oral mucosa, followed by careful dissection of the labial artery pedicle (**Figure 2**).

After a superior rotation and location of the retail in the previously prepared default, it was made the fixation on plans, maintaining the centralization of midline and stretching of the columella (**Figure 3**).

A year after the tongue septorhinoplasty, patient evolves without complication in the postoperative period (**Figure 4**).

Figure 5: Preoperative view showing bilateral palatine fissure. Demarcation of the surgical technique.

On the second surgical moment, it was proposed the palatoplasty using the technique of Von Langenbeck. Initially a retractor of Dingman Mouth was applied to allow better visualization of the operatory field, with subsequent demarcation of the incisions with methylene blue (**Figure 5**).

Figure 6: Immediate postoperative view of bilateral palatin fissure repaired by the technique of Von Langenbeck.

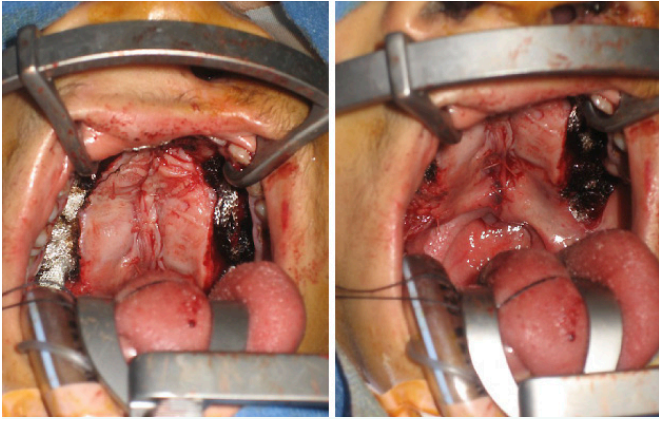
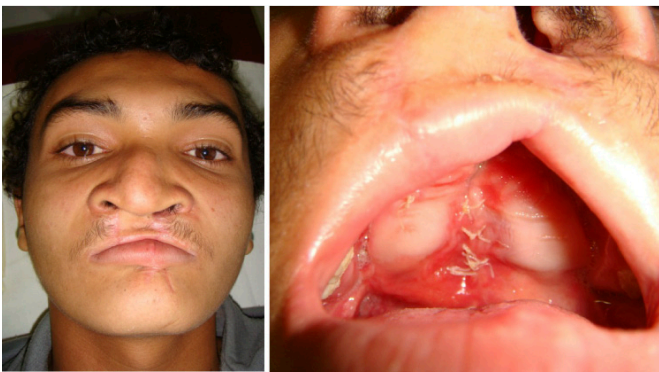

Figure 7: Postoperative clinical aspect.



After the appropriate demarcations, a full-thickness incision was made along the edge of the soft palate fissure extending to the base, preserving the muscles of the uvula, followed by the cautious repair of uvula's two layers, applying the uvuloplasty conventional technique. Secondary incisions were performed along the lateral edge of the hard palate, starting anteriorly near the palatomaxillary suture line, heading toward posterior direction, exactly medial to the alveolar crest with posterior incision of the mucosa along the fissure. The whole mucoperiosteal was then taken off carefully aiming the preservation of neurovascular pedicles, creating in this way bipedicle mucoperiosteal flaps along the fissure. In conclusion, the mucosa has been carefully sutured and margins were approximated. (Figure 6).

In postoperative follow-up of 2 months the patient is with good aesthetic-functional restabilization, expressing intense satisfaction with the results obtained. (Figure 7).

Discussion

Among the etiological factors of cleft lip/palate that are most frequently related to this pathology are: use of steroids, benzodiazepines, hypervitaminosis A, consanguinity, malnutrition, ionizing radiation, viruses, drug use, alcoholism, mechanical trauma and heredity. This is a pathology of multidisciplinary coverage, involving mainly the areas of Oral and Maxillofacial Surgery and Traumatology, Plastic surgery, orthodontics, psychology, nutritionist and speech therapy (KUHN, *et al.*, 2012; PERRY, 2015; KIM, *et al.*, 2015; EDUARDO, *et al.*, 2011; FURR, *et al.*, 2011).

Clinically and socially, disabled individuals with cleft lip/palate face problems of eating, swallowing, dysarthria, hypoplasia of the maxilla during growth, occlusal disharmony, low self-esteem and external appearances in different degrees. The corrective surgery, orthodontic treatment and speech therapy are necessary for the improvement of the clinical picture (MEHROTRA, 2015).

The treatment of patients with cleft should be initiated during the infant stage, before the individual begins to speak, providing a better joint production in addition to improving the development of voice and language (KHALIL *et al.*, 2009; LEE, *et al.*, 2012). The patient presented here lived his 22 years of age in the countryside in the South of Ceará state, geographically distant from the centres for rehabilitation of Craniofacial anomalies and under unfavourable circumstances, factors that led him to adulthood without proper treatment.

There are several surgical techniques that have been documented over the years to correct cleft lip uni or bilaterally. The option adopted by this author was the confection of Abbé flap, which it was first described by Sabbatini, in Italy, in 1837. It consists

in the correction of the total thickness of upper lip, using the lower lip flap based on the labial artery. The Abbé flap has several advantages including providing tissue for correction of all lip thickness, restores the local innervation, providing active function of the upper lip and in some cases, can simulate the filter, improving the aesthetic aspect (AKAMATSU, *et al.*, 2009; REIS FILHO, *et al.*, 2010; CARONE, *et al.*, 2009).

The use of the techniques of Abbé and Von Langenbeck to associated cleft lip and cleft palate have been rarely described, and in this case the combination of both techniques is an effective treatment, since surgeons have knowledge of the anatomy and physiology of the face in addition to meet the principles of surgical technique. The most important fact is to have "common sense", when to use it (PITANETO, *et al.*, 2015; PERRY, *et al.*, 2015).

Conclusion:

Rehabilitation of patients with clefts lip and palate must be made by an experienced multi-disciplinary team, being very important interdisciplinary professional rehabilitators.

The Abbé and Von Langenbeck techniques, when used in the repair of serious sequelae in cleft, show up as a good option in the therapeutic arsenal, providing satisfactory functional and esthetic result even in late rehabilitation.

The consequences of the disease, whether physical or psychological, must be minimized so that the patient feels able to integrate society.

References

- Farronato, G.; Kairyte, L.; Giannini, L.; Galbiati, G.; Maspero, C. How various surgical protocols of the unilateral cleft lip and palate influence the facial growth and possible orthodontic problems? What is the timing of lip, palate and alveolus repair? Literature Review. *Stomatologija, Baltic Dental and Maxillofacial Journal*, 2014; v. 16, p. 53-60.
- Monroy, PLC.; Grelte, S.; Kuijpers-Jagtman, AM.; Wagener FADTG.; Hoff, JWV. Strategies to Improve Regeneration of the Palate Muscles After Cleft Palate Repair. *Tissue Engineering*, 2012; v. 16(6), p. 468-477.
- Kuhn, VD.; Miranda, C.; Dalpian, DM.; Moraes, CMB.; Backes, DS.; Martins, JS.; Santos, BZ. Cleft Lip and Palate: Literature Review. *Disciplinarum Scientia*, 2012; v.12(2), p. 237-245.
- Ribeiro, EM.; Moreira, ASCG. Update about the multidisciplinary treatment of cleft lip and palate. *Revista Brasileira em Promoção da Saúde*, 2005; v. 18(1), p. 31-40.
- Silva, HA.; Bordon, AKCB.; Duarte, DA. Study of Cleft Lip Palate. Clinical Aspects and Repercussion. Considerations Related to its Therapy. *J Bras Odontopediatr Odontol Bebê*, 2002; V. 5(27), p. 432-436.
- Spina, V.; Psillakis, JM.; Lapa, Fs.; Ferreira, MC. Classification of cleft lip and cleft palate. Suggested Changes. *Rev Hosp Clin Fac Med São Paulo*, 1971; v. 27(1), p. 5-6.
- Alonso, N.; Tanikawa, DYS.; Lima-Junior, JE.; Ferreira, MC. Comparative and evolutive of attendance protocols of patients with cleft lip and palate. *Rev. Bras. Cir. Plást*, 2010; v. 25(3), p. 434-8.
- Ferreira, AG.; Diefenbach, RS.; Heitz, C. Intra-nasal ectopic tooth in the patient with cleft lip and palate - Report of 2 Cases. *R. Face. Odonto*, 2004; v. 45, p. 38-40.
- Reis, LFG.; Giovanini, A.; Namba, EL.; Silva, ELM.; Garcia, MA. Supernumerary teeth in the orthodontic treatment. *Revista Sul-Brasileira de Odontologia*, 2006; v. 3, p. 20-25.
- Pita-Neto, IC.; Franco, JMPL.; Bringel, RJS.; Santana, MDR.; Batista, HMT.; Pita, P.; Soares, ECS.; Abreu, LC.; Rodrigues, LMR. Transnasal Removal of Ectopic Supernumerary tooth from cleft Patient. *International Archives of Medicine*, 2015; v. 8, n. 8, p. 1-5.
- Kim, DW.; Chung, SW.; Jung, HD.; Jung, YS. Prenatal ultrasonographic diagnosis of cleft lip with or without cleft palate; pitfalls and considerations. *Maxillofacial Plastic and Reconstructive Surgery*, 2015; v. 37(24), p. 1-5.
- Perry, PR. Flap Necrosis after Palatoplasty in Patients with Cleft Palate. *BioMed Research International*, 2015; p. 1-14.
- Eduardo, C.; Amaral, R.; Kuczyński, E.; Alonso, N. Quality of life among children with cleft lips and palates: a critical review of measurement instruments. *Rev. Bras. Cir. Plást*, 2011; v. 26(4), p. 639-44.

- Furr, MC.; Larkim, E.; Blakeley, R.; Albert, TW.; Tsugawa, L.; Weber, SM. Extending Multidisciplinary Management of Cleft Palate to the Developing World. *Journal of Oral and Maxillofacial Surgery*, 2011; v. 69, p. 237-241.
- Mehrotra, D. Genomic expression in non syndromic cleft lip and palate patients: A review. *Journal of Oral Biology and Craniofacial Research*, 2015; p. 86-91.
- Khalil, W.; Castro, PHS.; Silva, AN.; Volpato, LER. Cleft lip and palate in an old patient: case report. *Rev. Clín. Pesq. Odontol*, 2009; v. 5, p. 67-71.
- Lee, DW.; Kim, YS.; Park, BY. Simultaneous Correction of Scars and Tissue Deficiency With Composite Grafts in Secondary Cleft Lip Deformity. *Journal of Oral and Maxillofacial Surgery*, 2012; v.70, p. 419-427.
- Akamatsu, T.; Tanaka, R.; Imagawa, K. Reconstruction of Wide Cleft Lip Scar by Flap and Advancement Flap from Lateral Upper Lip. *Tokai J Exp Clin Med*, 2009; v. 34(3), p. 117-121.
- Reis Filho, GC.; Arruda, AM.; Oliveira, CL.; Anbar, RA. Surgical Treatment of Sequel of Cleft Lip using Abbé Flap. *Rev. Bras. Cir. Plást*, 2010; v. 25(2), p. 398-400.
- Carone, DR.; Amaral, CER, Amaral, CAAR.; Menon, DN.; Amaral, MP.; Buzzo, CL. Abbé flap: Option on Bilateral cleft Treatment. How is done at Sobrapar. *Rev. Bras. Cir. Craniomaxilofac*, 2009; v. 12(3), p. 94-7.
- Perry, PR.; Flores, CO.; Gutierrez, AMG.; Nano, EG.; Rabanal, OC. A Comparative Study to Evaluate the Functional Effect of Unilateral Uvuloplasty afeter Primary Palatoplasty. *PRS Global Open*, 2015; p. 1-8.

Comment on this article:

<http://medicalia.org/>

Where Doctors exchange clinical experiences, review their cases and share clinical knowledge. You can also access lots of medical publications for free. **Join Now!**

Publish with iMedPub

<http://www.imed.pub>

International Archives of Medicine is an open access journal publishing articles encompassing all aspects of medical science and clinical practice. IAM is considered a megajournal with independent sections on all areas of medicine. IAM is a really international journal with authors and board members from all around the world. The journal is widely indexed and classified Q1 in category Medicine.