

Treatment with *Saccharomyces boulardii* reduces the inflammation and dysfunction of the gastrointestinal tract in 5-fluorouracil-induced intestinal mucositis in mice

Priscilla F. C. Justino¹, Luis F. M. Melo¹, Andre F. Nogueira¹, Jose V. G. Costa¹, Luara M. N. Silva¹, Cecila M. Santos¹, Walber O. Mendes¹, Marina R. Costa¹, Alvaro X. Franco¹, Aldo A. Lima¹, Ronaldo A. Ribeiro¹, Marcellus H. L. P. Souza¹ and Pedro M. G. Soares^{1,2*}

¹Department of Physiology and Pharmacology, Medical School, Federal University of Ceara, Rua Coronel Nunes de Melo 1315, Rodolfo Teofilo, Fortaleza, Ceara CEP 60.430-270, Brazil

²Department of Morphology, Medical School, Federal University of Ceara, Rua Delmiro de Farias s/n, Rodolfo Teofilo, Fortaleza, Ceara CEP 60.416-030, Brazil

(Submitted 16 April 2013 – Final revision received 3 October 2013 – Accepted 23 October 2013)

Abstract

Intestinal mucositis is an important toxic side effect of 5-fluorouracil (5-FU) treatment. *Saccharomyces boulardii* is known to protect from intestinal injury via an effect on the gastrointestinal microbiota. The objective of the present study was to evaluate the effect of *S. boulardii* on intestinal mucositis induced by 5-FU in a murine model. Mice were divided into saline, saline (control) + 5-FU or 5-FU + *S. boulardii* (16×10^9 colony-forming units/kg) treatment groups, and the jejunum and ileum were removed after killing of mice for the evaluation of histopathology, myeloperoxidase (MPO) activity, and non-protein sulfhydryl group (mainly reduced glutathione; GSH), nitrite and cytokine concentrations. To determine gastric emptying, phenol red was administered orally, mice were killed 20 min after administration, and the absorbance of samples collected from the mice was measured by spectrophotometry. Intestinal permeability was measured by the urinary excretion rate of lactulose and mannitol following oral administration. *S. boulardii* significantly reversed the histopathological changes in intestinal mucositis induced by 5-FU and reduced the inflammatory parameters: neutrophil infiltration (control 1.73 (SEM 0.37) ultrastructural MPO (UMPO)/mg, 5-FU 7.37 (SEM 1.77) UMPO/mg and 5-FU + *S. boulardii* 4.15 (SEM 0.73) UMPO/mg); nitrite concentration (control 37.00 (SEM 2.39) μM , 5-FU 59.04 (SEM 11.41) μM and 5-FU + *S. boulardii* 37.90 (SEM 5.78) μM); GSH concentration (control 477.60 (SEM 25.25) $\mu\text{g}/\text{mg}$, 5-FU 270.90 (SEM 38.50) $\mu\text{g}/\text{mg}$ and 5-FU + *S. boulardii* 514.00 (SEM 38.64) $\mu\text{g}/\text{mg}$). Treatment with *S. Boulardii* significantly reduced the concentrations of TNF- α and IL-1 β by 48.92 and 32.21 % in the jejunum and 38.92 and 61.79 % in the ileum. In addition, *S. boulardii* decreased the concentrations of chemokine (C-X-C motif) ligand 1 by 5-fold in the jejunum and 3-fold in the ileum. Interestingly, *S. boulardii* reduced the delay in gastric emptying (control 25.21 (SEM 2.55)%, 5-FU 54.91 (SEM 3.43)% and 5-FU + *S. boulardii* 31.38 (SEM 2.80)%) and induced the recovery of intestinal permeability (lactulose:mannitol ratio: control 0.52 (SEM 0.03), 5-FU 1.38 (SEM 0.24) and 5-FU + *S. boulardii* 0.62 (SEM 0.03)). In conclusion, *S. boulardii* reduces the inflammation and dysfunction of the gastrointestinal tract in intestinal mucositis induced by 5-FU.

Key words: Intestinal mucositis; 5-Fluorouracil; *Saccharomyces boulardii*; Probiotics; Inflammation

Probiotics have been defined as 'live microorganisms that, when administered in adequate amounts, confer a health benefit to the host'⁽¹⁾. Probiotics promote crypt cell proliferation, prevent cytokine-induced apoptosis⁽²⁾, reduce pro-inflammatory cytokine production and regulate the intestinal immune system⁽³⁾. *Saccharomyces boulardii* is a probiotic thermophilic non-pathogenic yeast⁽⁴⁾ that is widely used in the treatment of gastrointestinal disorders associated with diarrhoea of varying aetiology^(5,6). In a study on irinotecan-induced intestinal

mucositis, Sezer *et al.*⁽⁷⁾ found that the administration of *S. boulardii* reduced the severity of intestinal mucositis by significantly decreasing leucocyte migration and inflammation.

Mucositis is a major oncological problem associated with the cytotoxicity of chemotherapy and radiotherapy. According to Duncan & Grant⁽⁸⁾, the development of intestinal mucositis may be divided into the following stages: the inflammatory stage; the epithelial degradation stage; the ulceration/bacterial stage, followed by the re-establishment of functional epithelia.

Abbreviations: 5-FU, 5-fluorouracil; CFU, colony-forming units; CXCL, chemokine (C-X-C motif) ligand; MPO, myeloperoxidase; PAF, platelet-activating factor; TUNEL, transferase-mediated dUTP nick-end labelling; UMPO, ultrastructural myeloperoxidase.

* **Corresponding author:** Dr P. M. G. Soares, email pedrogsoares@yahoo.com.br

The anti-metabolite agent 5-fluorouracil (5-FU) is used in the treatment of a range of cancers, including colorectal and breast cancers^(9,10), but it is known to induce intestinal damage, especially intestinal mucositis⁽¹¹⁾, and intestinal stem cell apoptosis⁽¹²⁾. Using an animal model, Soares *et al.*⁽¹³⁾ found that 5-FU-induced intestinal mucositis was associated with neutrophil infiltration, increased levels of pro-inflammatory cytokines and a significant delay in gastric emptying. However, there are no previous studies that have evaluated the effect of treatment with *S. boulardii* on the inflammatory and functional aspects of 5-FU-induced intestinal mucositis, which is the objective of the present study.

Materials and methods

Animals

Male Swiss mice weighing 25–30 g (supplied by the Department of Physiology and Pharmacology, UFC Medical School) were kept in a temperature-controlled room with access to water *ad libitum* and were fasted for 24 h before all experiments. The study was approved by a local research ethics committee (protocol #34/10), and all procedures involving animals were carried out in accordance with the Guide for the Care and Use of Laboratory Animals of the US Department of Health and Human Services.

Model of intestinal mucositis induced by 5-fluorouracil

Mice were randomly assigned to one of the following three groups comprising eight mice each: saline (control); saline + 5-FU (450 mg/kg, single dose, intraperitoneally); 5-FU + *S. boulardii* (16×10^9 colony-forming units (CFU)/kg) (Merck) for 3 d. Mice were killed 3 d after treatment with *S. boulardii*. Blood samples were collected, and the jejunum and ileum were removed for analyses of morphology and histopathology and determination of apoptosis, myeloperoxidase (MPO) activity, and non-protein sulfhydryl group, nitrite and cytokine (TNF- α , IL-1 β and chemokine (C-X-C motif) ligand 1 (CXCL-1)) concentrations. Diarrhoea occurrence and weight were recorded daily throughout the study in mice. Weight (g) is expressed as the percentage of weight loss compared with the control group.

Leucocyte count

Mice were anaesthetised before the collection of blood samples, which was performed by heart puncture. The total number of leucocytes was determined after dilution of blood samples in Turk's solution using a Neubauer chamber. Results are expressed as leucocytes/ml.

Intestinal morphometry, histopathology and apoptosis assay

Segments of the jejunum (3 cm segment immediately distal to the ligament of Treitz) and distal ileum (6 cm segment adjacent to the ileocaecal valve) were collected, fixed and stained with

haematoxylin and eosin for the measurement of villus height and crypt depth. For each sample, ten intact and well-oriented villi and crypts were measured and averaged. Microscopy was double blinded. Mucosal inflammation was assessed using a modification of the histopathological scores described by Macpherson & Pfeiffer⁽¹⁴⁾ and was graded as follows: 0, normal histological findings; 1, villus blunting, loss of crypt architecture, sparse inflammatory cell infiltration, vacuolisation and oedema; 2, villus blunting with fattened and vacuolated cells, crypt necrosis, intense inflammatory cell infiltration, vacuolisation and oedema; 3, villus blunting with fattened and vacuolated cells, crypt necrosis, intense inflammatory cell infiltration, vacuolisation and oedema. Cell apoptosis in the jejunal and ileal segments was detected by terminal deoxynucleotidyl transferase-mediated dUTP nick-end labelling (TUNEL) assay using the *In situ* Apoptosis Detection Kit (Millipore) according to the manufacturer's instructions. Results are expressed as the presence or absence of TUNEL-positive cells.

Determination of intestinal myeloperoxidase activity

MPO is primarily found in azurophilic neutrophil granules and has been extensively used as a biochemical marker of infiltration of granulocytes into various tissues, including the gastrointestinal tract. The extent of neutrophil accumulation in the intestinal mucosa was quantified using a MPO activity assay kit⁽¹⁵⁾. Briefly, intestinal tissue (50 mg/ml) was homogenised in hexadecyltrimethylammonium bromide buffer (Sigma). The homogenate was centrifuged at 4500 rpm for 7 min at 4°C. MPO activity in the resuspended pellet was assayed by measuring the change in absorbance at 450 nm using *o*-dianisidine dihydrochloride (Sigma) and 1% H₂O₂ (Merck). Results are expressed as units/mg tissue. A unit of MPO was defined as the amount of enzyme required to convert 1 μ mol/min H₂O₂ into water at 22°C.

Determination of sulfhydryl group concentrations

The concentrations of non-protein sulfhydryl groups (mainly reduced glutathione) in intestinal tissues were assessed using an assay for non-protein sulfhydryl content⁽¹⁶⁾. Briefly, 100 mg/ml of frozen intestinal tissue were homogenised in 0.02 M-EDTA. Aliquots of 400 μ l homogenate were mixed with 320 μ l of distilled water and 80 μ l of 50% TCA to precipitate the proteins. The mixture was centrifuged (3000 rpm) for 15 min at 4°C. Aliquots of 400 μ l of supernatant were mixed with 800 μ l of 0.4 M-Tris buffer (pH 8.9) and 20 μ l of 5,5-dithiobis-(2-nitrobenzoic acid) (Fluka), followed by shaking for 3 min. Within 5 min of the addition of 5,5-dithiobis-(2-nitrobenzoic acid), absorbance was read at 412 nm against a blank reagent without the homogenate. Results are expressed as μ g/mg tissue.

Determination of nitrite concentrations

The production of NO was determined indirectly by measuring nitrite concentrations based on the Griess reaction⁽¹⁷⁾.

Briefly, 100 μl of intestinal tissue homogenate were incubated with 100 μl of Griess reagent (1% sulphanilamide in 1% H_3PO_4 -0.1% *N*-(1-naphthyl)ethylenediamine dihydrochloride-1% H_3PO_4 -distilled water, 1:1:1:1) at room temperature for 10 min. Absorbance was measured at 540 nm in a microplate reader. Nitrite concentrations were determined from a standard nitrite curve generated using NaNO_2 .

Determination of cytokine (TNF- α , IL-1 β and chemokine (C-X-C motif) ligand 1) concentrations

The concentrations of cytokines (TNF- α , IL-1 β and CXCL-1) in duodenum samples were determined by ELISA using protocols supplied by the manufacturer (R&D Systems). Results are expressed as pg/ml.

Measurement of gastric emptying and intestinal transit

Gastric emptying and intestinal transit were measured using the modified technique of Reynell & Spray⁽¹⁸⁾. Mice were fed 300 μl of a test meal consisting of a non-absorbable marker (0.75 mg/ml phenol red in 5% glucose). After 20 min, mice were killed by cervical dislocation. After laparotomy, the stomach and bowels were exposed and the oesophageal-gastric, gastroduodenal and ileocaecal junctions were immediately isolated by ligatures. The specimens were then moved onto a table and divided into stomach and proximal, medial and distal bowel segments. Each segment was placed in a graduated cylinder, and the total volume was measured by adding 10 ml of 0.1 M-NaOH. The samples were then cut into small pieces and homogenised for 30 s. After 20 min, 1 ml of supernatant was removed and centrifuged for 10 min at 2800 rpm. The proteins in the homogenate were precipitated by adding 20% TCA and separated by centrifugation for 20 min at 2800 rpm. Then, 150 ml of supernatant were added to 200 ml of 0.5 M-NaOH. The absorbance of the samples was determined by spectrophotometry at a wavelength of 540 nm, and it is expressed as optical density.

Fractional dye retention is expressed as a percentage, according to the following equation:

Gastric dye retention

$$= \frac{\text{amount of phenol red recovered in stomach}}{\text{total amount of phenol red recovered from two segments (stomach and small intestine)}}$$

Intestinal transit was calculated for each bowel segment by dividing the amount of phenol red recovered from a given segment by the amount of phenol red recovered from all the three segments, and it is expressed as a percentage.

Determination of intestinal absorption and permeability

After an overnight fast (6–8 h), mice were administered 2 ml of a solution containing lactulose (200 mg/ml) and mannitol (50 mg/ml) by gavage needle. After 1 h, mice were given access to food and water *ad libitum*. Urine samples were

collected for the next 24 h in a flask with 25 μl of a solution containing chlorhexidine (40 mg/ml). Total urine volume was recorded, and two aliquots were stored at -20°C . Each urine sample (50 μl) was mixed with 50 μl of a solution containing melibiose (3.6 mM) and diluted in 2.9 ml of twice-distilled and deionised water. After centrifugation and filtration via a Millipore membrane (0.22 μm), 50 μl were employed for sugar determination using HPLC with pulsed amperometric detection as described previously⁽¹⁹⁾. The urinary recovery of both lactulose and mannitol was calculated as a percentage of the dose ingested. Both these sugars are hydrophilic and have a low affinity for the monosaccharide transport system and, thus, are absorbed passively in a non-mediated fashion and excreted in the urine⁽²⁰⁾. Mannitol, a monosaccharide, has a radius of 0.4 nm and is absorbed transcellularly through aqueous pores in the cell membrane, reflecting the total epithelial absorptive surface area. By contrast, lactulose, a disaccharide with a radius of 0.52 nm, is absorbed paracellularly via extrusion zones at villus tips and tight junctions, reflecting the disruption of intestinal barrier function⁽²¹⁾.

Statistical analysis

Results are reported as means with their standard errors for each group. Data were submitted to ANOVA followed by Bonferroni's test (parametric data) or the Kruskal–Wallis test and Dunn's test (non-parametric data). The level of statistical significance was set at $P < 0.05$.

Results

Effects of *Saccharomyces boulardii* on intestinal mucositis induced by 5-fluorouracil

Initially, a dose–response analysis was carried out for *S. boulardii* (1.78×10^9 , 5.34×10^9 , 16×10^9 and 48×10^9 CFU/kg). An increase in weight was observed in the control group throughout the study period. By contrast, the weight of the 5-FU group decreased considerably (9.75 (SEM 0.58)%) on day 3 after 5-FU administration compared with that of the control group. Treatment with *S. boulardii* at doses 1.78×10^9 and 5.34×10^9 CFU/kg did not reverse the weight loss in the 5-FU group; however, treatment with *S. boulardii* at doses 16×10^9 and 48×10^9 CFU/kg significantly prevented ($P < 0.05$) weight loss in the 5-FU group. Thus, we chose to use a submaximal dose (16×10^9 CFU/kg) for all the other experiments (Table 1). Stools suggestive of diarrhoea were observed in the ileal segments of the 5-FU group. It was possible to detect the presence of solid faeces in the saline and 5-FU + *S. boulardii* groups compared with the 5-FU group (Fig. 1).

Significant leucopenia was observed on day 3 after 5-FU administration (1675 (SEM 138) cells/ mm^3) compared with the control (5289 (SEM 851) cells/ mm^3). Treatment with *S. boulardii* did not prevent 5-FU-induced leucopenia (2825 (SEM 303) cells/ mm^3).

Table 1. Reduction of weight loss (%) by *Saccharomyces boulardii* in mice with 5-fluorouracil (5-FU)-induced intestinal mucositis (Mean values with their standard errors)

Groups (n 8)	Study period (d)					
	1st		2nd		3rd	
	Mean	SEM	Mean	SEM	Mean	SEM
Saline	0		0		0	
5-FU	4.42	0.46	7.66	0.49	11.17	0.83
5-FU + <i>S. boulardii</i> (1.78×10^9 CFU/kg)	6.22	0.82	8.05	0.67	10.04	0.82
5-FU + <i>S. boulardii</i> (5.34×10^9 CFU/kg)	4.29	0.96	6.79	0.57	7.69	0.99
5-FU + <i>S. boulardii</i> (16×10^9 CFU/kg)	0.65*	0.77	3.39*	0.57	3.22*	0.76
5-FU + <i>S. boulardii</i> (48×10^9 CFU/kg)	2.17*	0.61	6.16	0.61	2.98*	0.64

CFU, colony-forming units.

* Mean value was significantly different from that of the 5-FU group ($P < 0.05$).

Effects of *Saccharomyces boulardii* on histopathological changes in intestinal mucosa

Compared with the control group, the 5-FU group presented the following histopathological changes in the jejunum and ileum: mucosa with shortened villi with vacuolated cells; crypt necrosis; intense inflammatory cell infiltration; vacuolisation; oedema. Histopathological changes induced by 5-FU were significantly reversed in the 5-FU + *S. boulardii* group, as demonstrated by the microscopic scores (Table 2). The photomicrographs in Fig. 2 show intense inflammatory cell infiltration, vacuolisation and oedema in the jejunum (Fig. 2(e)) and ileum (Fig. 2(g)) of the 5-FU group compared with the control group (Fig. 2(a) and (c)). Treatment with *S. boulardii* for 3 d (Fig. 2(i) and (l)) reversed the changes in both segments. Furthermore, 5-FU markedly increased the apoptosis of intestinal crypt cells in the jejunum (Fig. 2(f)) and ileum (Fig. 2(h)) compared with the control (Fig. 2(b) and (d)), which was prevented by treatment with *S. boulardii* (Fig. 2(j) and (m)).

5-FU induced a significant decrease in the villus height (Fig. 3(a)), an increase in the crypt depth (Fig. 3(b)) and a decrease in the villus:crypt ratio (Fig. 3(c)) in the jejunum and ileum compared the control. Figure 3(b) shows that treatment with *S. boulardii* reversed the 5-FU-induced increase in crypt depth in both segments. Similarly, the decrease in the villus:crypt ratio observed in the 5-FU group was significantly reversed by treatment with *S. boulardii* (Fig. 3(c)).

Effects of *Saccharomyces boulardii* on myeloperoxidase activity and on reduced glutathione and nitrite concentrations

Following the administration of 5-FU, we observed a significant increase in neutrophil infiltration in the jejunum (5.87 (SEM 1.06) ultrastructural MPO (UMPO)/mg) and ileum (14.09 (SEM 2.99) UMPO/mg) compared with the control (jejunum 1.73 (SEM 0.36) UMPO/mg and ileum 1.51 (SEM 0.17) UMPO/mg). Treatment with *S. boulardii* reduced neutrophil infiltration in the jejunum (3.08 (SEM 0.46) UMPO/mg) and ileum (3.67 (SEM 0.85) UMPO/mg) (Fig. 4(a)).

In 5-FU-treated mice, we detected significantly reduced glutathione concentrations in the jejunum (270.90 (SEM

38.50) $\mu\text{g}/\text{mg}$) and ileum (46.01 (SEM 6.30) $\mu\text{g}/\text{mg}$) compared with those in the control mice (jejunum 477.60 (SEM 25.20) $\mu\text{g}/\text{mg}$ and ileum 186.80 (SEM 22.80) $\mu\text{g}/\text{mg}$), an effect that was reversed after treatment with *S. boulardii* by 52.43% (521.30 (SEM 48.53) $\mu\text{g}/\text{g}$) in the jejunum and by 52.94% (144.90 (SEM 29.83) $\mu\text{g}/\text{g}$) in the ileum (Fig. 4(b)).

Figure 4(c) shows that 5-FU increased nitrite concentrations in the jejunum (86.43 (SEM 10.93) μM) and ileum (44.66 (SEM 5.46) μM) compared with the control (37.00 (SEM 2.39) and 25.08 (SEM 1.38) μM , respectively). By contrast, treatment with *S. boulardii* reduced nitrite concentrations in the jejunum and ileum (40.28 (SEM 9.85) and 32.26 (SEM 5.23) μM , respectively).

Effects of *Saccharomyces boulardii* on TNF- α , IL-1 β and chemokine (C-X-C motif) ligand 1 production

As shown in Fig. 5(a) and (b), in mice with intestinal mucositis induced by 5-FU, the concentrations of TNF- α and IL-1 β




Fig. 1. Prevention of diarrhoea by *Saccharomyces boulardii* in mice with 5-fluorouracil-induced intestinal mucositis. Stools suggestive of diarrhoea were observed in the ileal segments of the 5-fluorouracil (5-FU) group. The image shows the presence of solid faeces (arrows) in the saline and 5-FU + *S. boulardii* groups compared with the 5-FU group.

Table 2. Attenuation of histopathological parameters by *Saccharomyces boulardii* in mice with 5-fluorouracil (5-FU)-induced intestinal mucositis (Median scores and ranges)

Groups (n 8)	Jejunum		Ileum	
	Median	Range	Median	Range
Saline	0	0–1	0	0–1
5-FU	2.5*	1–3	2.5*	1–3
5-FU + <i>S. boulardii</i>	1†	0–2	0†	0–1

* Median value was significantly different from that of the saline group ($P < 0.05$).

† Median value was significantly different from that of the 5-FU group ($P < 0.05$).

increased significantly ($P < 0.05$) in the jejunum (56.34 and 81.73%, respectively) and ileum (195.44 and 107.45%, respectively) compared with those in the control mice. Similarly, CXCL-1 concentrations were increased by 5-fold in the jejunum and 3-fold in the ileum. By contrast, treatment with *S. boulardii* significantly ($P < 0.05$) reduced TNF- α and IL-1 β concentrations by 48.92 and 32.21% in the jejunum and by 38.92 and 61.79% in the ileum, respectively. Treatment with *S. boulardii* decreased CXCL-1 concentrations by 5-fold in the jejunum (198.9 (SEM 151.5) pg/ml) and by 3-fold in the ileum (376.6 (SEM 107.1) pg/ml) (Fig. 5(c)).

Effects of Saccharomyces boulardii on gastric emptying and gastrointestinal transit

Gastric retention was significantly ($P < 0.05$) higher in mice with intestinal mucositis induced by 5-FU (54.91 (SEM 3.42)%) than in the control group (25.21 (SEM 2.55)%) (Fig. 6(a)). This change was reversed by treatment with *S. boulardii* (31.38 (SEM 2.79)%). Fig. 6(b) shows a significant level of retention in the proximal, medial and distal bowel segments (5-FU *v.* saline) associated with diarrhoea. Treatment with *S. boulardii* reversed these changes. We observed that *S. boulardii* alone had no effect on gastric emptying, but had a mild effect on medial bowel segments. However, the intestinal transit curve of *S. boulardii* alone had a course similar to that of the intestinal transit curve of saline.

Similarly, gastrointestinal transit was significantly slower in the 5-FU group than in the saline group (median geometric centre: 1.83 (SEM 0.07) *v.* 2.32 (SEM 0.08); $P < 0.05$), but was normalised by treatment with *S. boulardii* (2.31 (SEM 0.06)) (Fig. 6(c)).

Effects of Saccharomyces boulardii on intestinal absorption and permeability

In mice treated with 5-FU, the excretion of mannitol was reduced to 4.96 (SEM 1.24)% compared with that in the saline-treated mice (9.54 (SEM 2.10)%; Fig. 7(a)).

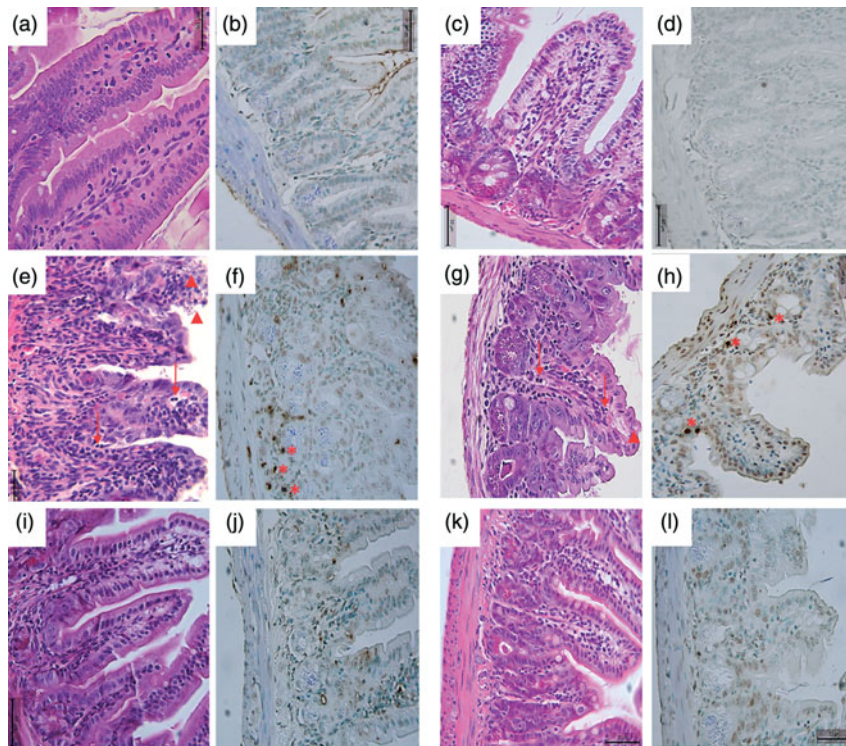


Fig. 2. Attenuation of intestinal damage and apoptosis by *Saccharomyces boulardii* in mice with 5-fluorouracil-induced intestinal mucositis. Photomicrographs (400 \times , scale 50 μ m) showing the jejunum and ileum of mice in the (a–d) control, (e–h) 5-fluorouracil (5-FU, 450 mg/kg, single dose, intraperitoneally) and (i–l) 5-FU + *S. boulardii* (16×10^9 colony-forming units/kg) groups treated for 3 d. (e, g) 5-FU induced shortening of the villi, deepening of the crypts, intense inflammatory cell infiltration (arrows), vacuolisation and oedema (arrowheads). Apoptosis was assessed using transferase-mediated dUTP nick-end labelling (TUNEL) assay and 5-FU was found to increase the number of TUNEL-positive cells in the (f) jejunum (*) and (h) ileum (*). Treatment with *S. boulardii* reverted these alterations.

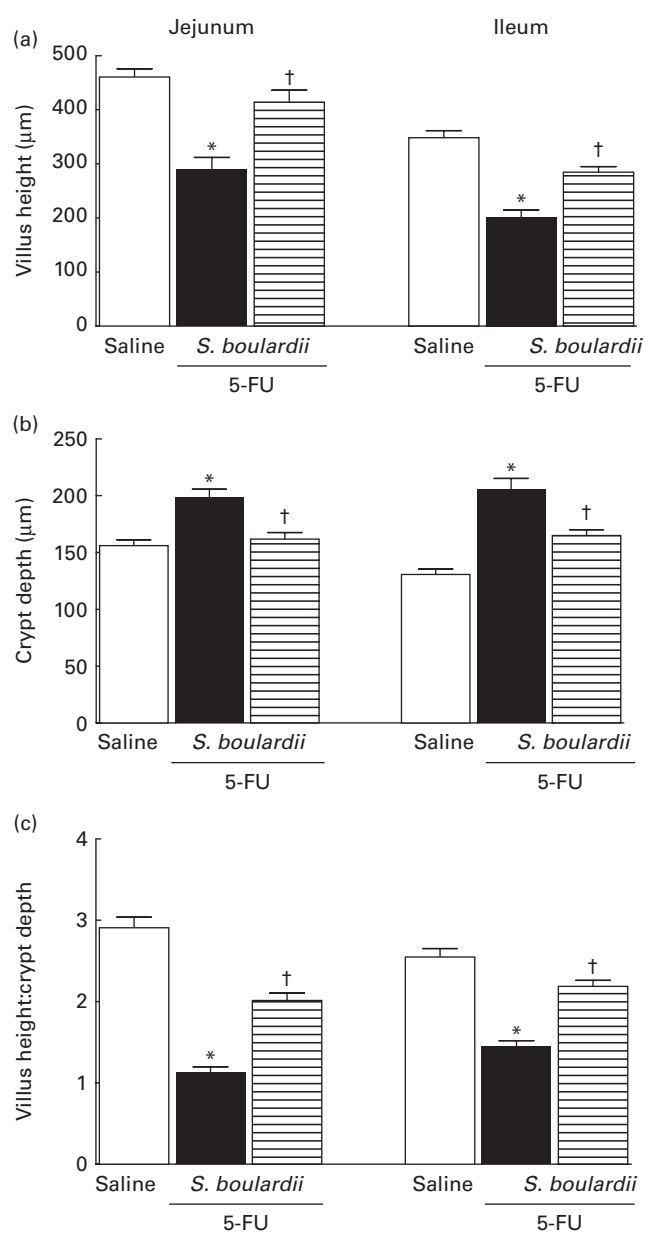


Fig. 3. Reversion of 5-fluorouracil (5-FU)-induced intestinal morphometric changes by *Saccharomyces boulardii* in mice. Segments of the jejunum and ileum were retrieved to measure (a) villus height, (b) crypt depth and (c) the villus: crypt ratio. Values are means, with their standard errors represented by vertical bars. *Mean value was significantly different from that of the saline group ($P < 0.05$; ANOVA followed by Bonferroni's test). †Mean value was significantly different from that of the 5-FU group ($P < 0.05$; ANOVA followed by Bonferroni's test).

This reduction in mannitol absorption following 5-FU administration reflects a substantial decrease in the mucosal absorptive area. Mice treated with 5-FU exhibited an increase in lactulose excretion (6.60 (SEM 2.05)%), but this increased excretion was not significantly different from excretion in the saline-treated group (3.65 (SEM 0.95)%) (Fig. 7(b)). Additionally, the lactulose:mannitol ratio was significantly ($P < 0.05$) increased in the 5-FU-treated group than in the control group (1.38 (SEM 0.24) *v.* 0.52 (SEM 0.03)), but was normalised by treatment with *S. boulardii* (0.62 (SEM 0.03)) (Fig. 7(c)).

Discussion

In the present study, treatment with *S. boulardii* was able to prevent diarrhoea and weight loss, which are important symptoms of intestinal mucositis induced by 5-FU. In addition, treatment with *S. boulardii* significantly decreased apoptosis and reversed histopathological changes in murine intestinal mucositis induced by 5-FU, partly due to reductions in inflammatory parameters (concentrations of nitrite, reduced glutathione and cytokines and infiltration of neutrophils). Interestingly, *S. boulardii* also reversed 5-FU-induced gastrointestinal function alterations (gastric emptying, gastrointestinal transit, and intestinal absorption and permeability). Our findings

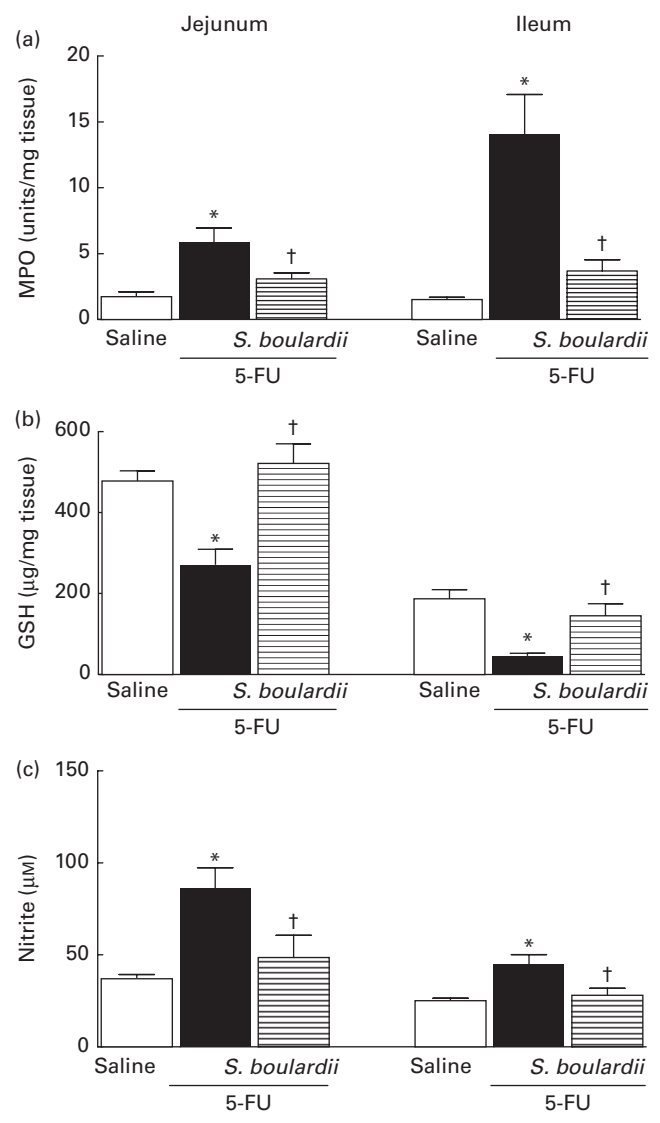


Fig. 4. Attenuation of inflammatory parameters (myeloperoxidase (MPO), reduced glutathione (GSH) and nitrite) by *Saccharomyces boulardii* in mice with 5-fluorouracil (5-FU)-induced intestinal mucositis. There were increased levels of (a) MPO activity, (b) GSH consumption and (c) nitrite due to exposure to 5-FU. (a–c) Treatment with *S. boulardii* for 3 d attenuated the inflammatory parameters. Values are means, with their standard errors represented by vertical bars. *Mean value was significantly different from that of the saline group ($P < 0.05$; ANOVA followed by Bonferroni's test). †Mean value was significantly different from that of the 5-FU group ($P < 0.05$; ANOVA followed by Bonferroni's test).

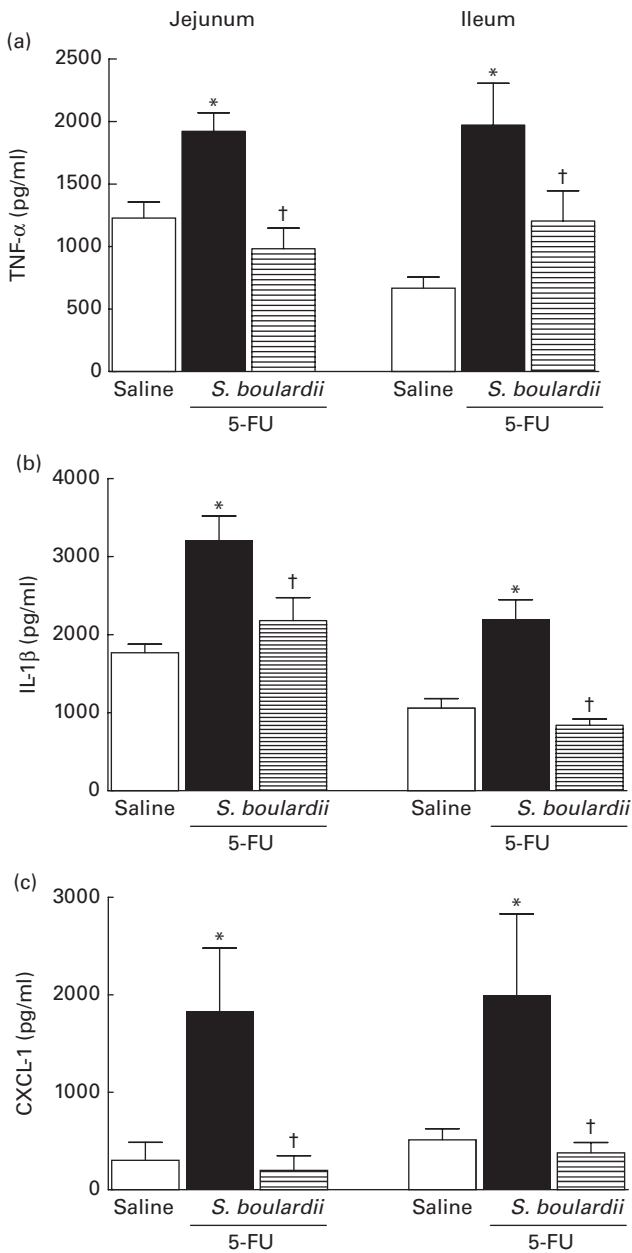


Fig. 5. Reduction of the increased concentrations of TNF- α , IL-1 β and chemokine (C-X-C motif) ligand 1 (CXCL-1) by *Saccharomyces boulardii* in mice with 5-fluorouracil (5-FU)-induced intestinal mucositis. There were increased concentrations of (a) TNF- α , (b) IL-1 β and (c) CXCL-1 due to exposure to 5-FU. (a, b and c) Treatment with *S. boulardii* for 3 d reduced the concentrations of pro-inflammatory cytokines. Values are means, with their standard errors represented by vertical bars. * Mean value was significantly different from that of the saline group ($P < 0.05$; ANOVA followed by Bonferroni's test). † Mean value was significantly different from that of the 5-FU group ($P < 0.05$; ANOVA followed by Bonferroni's test).

are in part consistent with those of Sezer *et al.*⁽⁷⁾, who observed significantly lower levels of leucocyte migration and inflammation in a model of irinotecan-induced intestinal mucositis treated with *S. boulardii*. Nevertheless, this study did not investigate the role of *S. boulardii* in the altered function of the gastrointestinal tract in mucositic intestines.

Epithelial damage and neutrophil infiltration in the mucosa during the inflammatory stage of mucositis have been observed

in several other studies⁽²²⁾. Mucositis induced by anti-neoplastic drugs destroys epithelial cells, subsequently inducing a local inflammatory response^(22,23). Using an *ex vivo* model, Edens *et al.*⁽²⁴⁾ found that the migration of neutrophils to epithelial cells can induce changes in the permeability of the intestinal epithelium, possibly explaining the finding of dyspepsia in animals with 5-FU-induced intestinal mucositis.

In a hamster model of oral mucositis induced by 5-FU, Lima *et al.*⁽²⁵⁾ observed important macroscopic and microscopic lesions and increased MPO activity, which could be inhibited

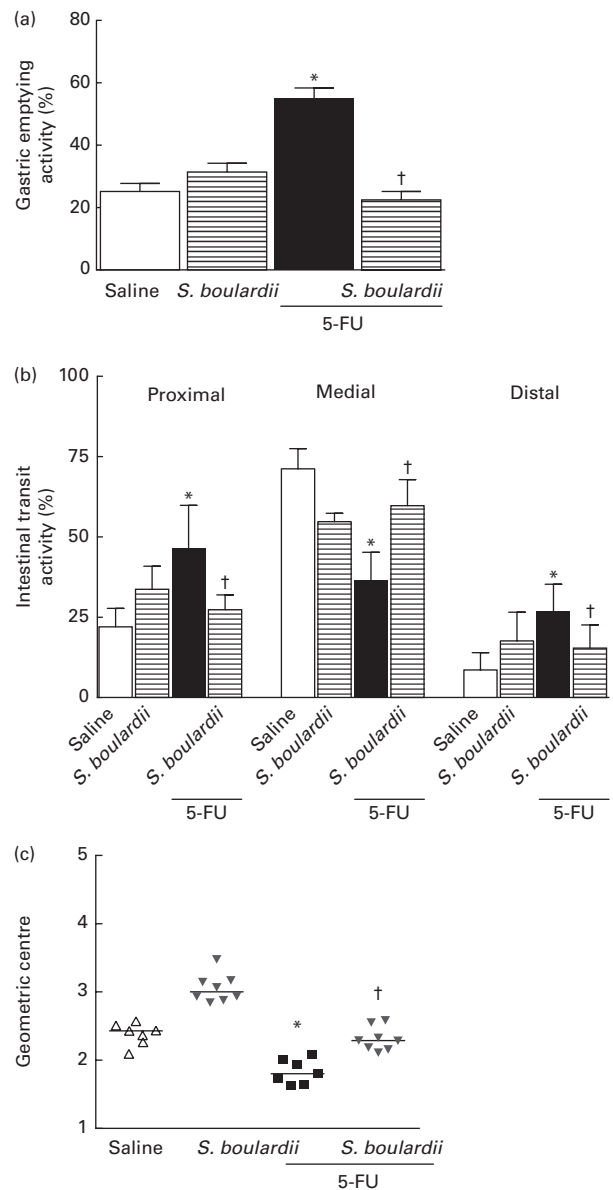


Fig. 6. Reversion of delayed gastric emptying and gastrointestinal transit associated with 5-fluorouracil (5-FU)-induced intestinal mucositis by *Saccharomyces boulardii* in mice. Significantly (a) delayed gastric emptying and (b) intestinal transit due to exposure to 5-FU and (c) displacement of the geometric centre were observed. (a–c) Treatment with *S. boulardii* for 3 d attenuated gastrointestinal disorders. Values are means, with their standard errors represented by vertical bars. * Mean value was significantly different from that of the saline group ($P < 0.05$; ANOVA followed by Bonferroni's test). † Mean value was significantly different from that of the 5-FU group ($P < 0.05$; ANOVA followed by Bonferroni's test).

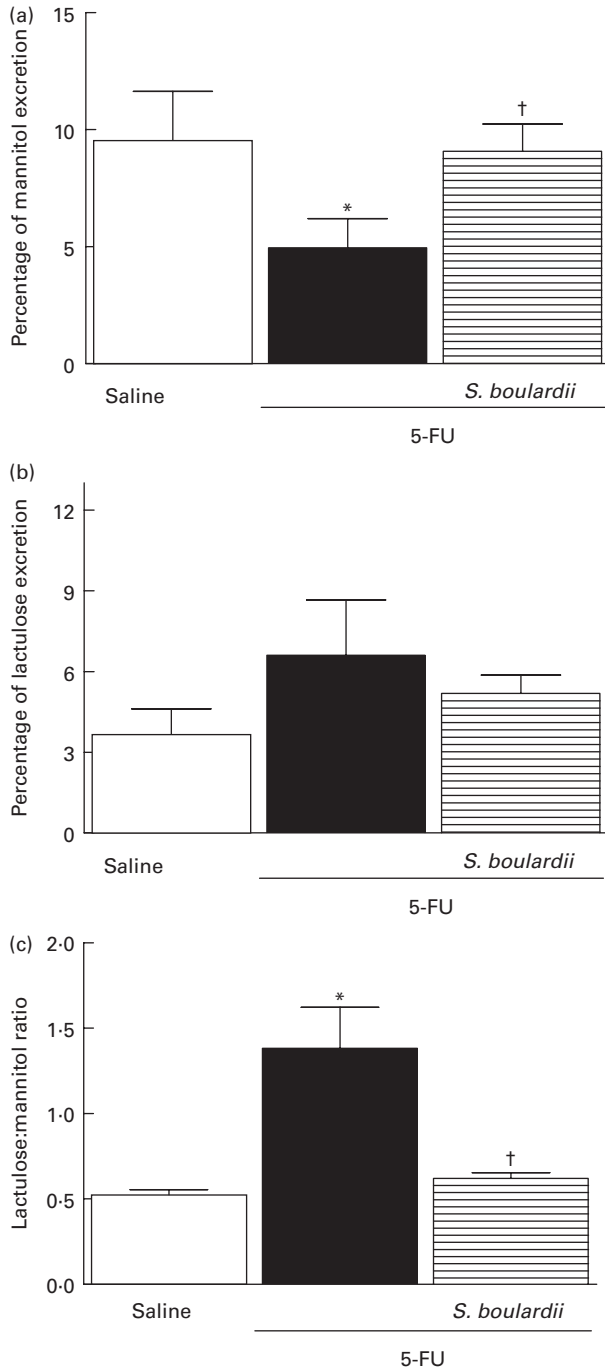


Fig. 7. Induction of the recovery of the integrity of the intestinal barrier in mice treated with 5-fluorouracil (5-FU) by *Saccharomyces boulardii*. Intestinal absorption and permeability were evaluated by lactulose/mannitol test. After treatment with 5-FU (450 mg/kg, single dose, intraperitoneally) or 5-FU + *S. boulardii* for 3 d, mice were administered a solution containing lactulose (200 mg/ml) and mannitol (50 mg/ml). (a) There was a significant reduction in the percentage of mannitol excretion induced by 5-FU treatment. (b) 5-FU induced changes, but not significantly, in the intestinal lactulose urinary excretion. (c) There was a marked increase in the lactulose:mannitol ratio induced by 5-FU. (a)–(c) Treatment with *S. boulardii* for 3 d reversed permeability alterations. Values are means, with their standard errors represented by vertical bars. * Mean value was significantly different from that of the saline group ($P < 0.05$; ANOVA followed by Bonferroni's test). † Mean value was significantly different from that of the 5-FU group ($P < 0.05$; ANOVA followed by Bonferroni's test).

by treatment with pentoxifylline and thalidomide. Another study using methotrexate revealed a significant increase in villous atrophy in rat intestinal mucosa after treatment⁽²⁶⁾. Intestinal injury may include brush-border hydrolase activity changes, blunted villus height, crypt deepening and increased crypt cell apoptosis with decreased proliferation^(27,28).

Prisciandaro *et al.*⁽²⁹⁾ reported that probiotic supernatants derived from *Escherichia coli* Nissle 1917 and *Lactobacillus fermentum* BR11 lowered the histological scores and MPO activity levels in the jejunum of rats treated with 5-FU. Smith *et al.*⁽³⁰⁾ successfully reversed inflammation (as demonstrated by a decrease in MPO activity) using *Lactobacillus fermentum* BR11, thereby reducing the severity of 5-FU-induced intestinal mucositis in the rat jejunum. Moreover, treatment with *S. boulardii* has been shown to reverse increased serum nitrate and nitrite concentrations in models of gastrointestinal damage induced by non-steroidal anti-inflammatory drugs⁽³¹⁾.

In a study of colitis in mice induced by *Citrobacter rodentium*, Wu *et al.*⁽³²⁾ demonstrated that treatment with *S. boulardii* significantly attenuated weight loss, lowered intestinal crypt hyperplasia and histological damage scores, and reduced MPO activity. Canonici *et al.*⁽³³⁾ observed that *S. boulardii* secretes substances capable of increasing enterocyte migration, regardless of cell proliferation. This increase in migration was associated with the ability of *S. boulardii* to promote cellular–extracellular matrix interactions.

In the present study, *S. boulardii* significantly reduced the concentrations of pro-inflammatory cytokines (IL-1 β and CXCL-8) in the mouse jejunal and ileal segments that were increased by the administration of 5-FU, in correlation with previous findings regarding gastric inflammation. Melo *et al.*⁽³⁴⁾ found TNF- α , IL-1 β and CXCL-1 to be important mediators in the pathogenesis of intestinal mucositis induced by irinotecan and concluded that treatment with pentoxifylline and thalidomide had a protective effect on intestinal structures. More recently, Soares *et al.*⁽³⁵⁾ evaluated the role of platelet-activating factor (PAF) in the pathogenesis of intestinal mucositis induced by 5-FU using PAF receptor knockout mice and a PAF receptor antagonist (BN52021). The intestinal mucosa of mice treated with PAF receptor antagonist was shown to be protected against damage caused by exposure to 5-FU.

Fidan *et al.*⁽³⁶⁾ concluded that the administration of *S. boulardii* may have a protective effect against diarrhoeal pathogens by reducing the pro-inflammatory response. The authors observed decreased secretion of pro-inflammatory cytokines (IL-1 β) in animals treated with *S. boulardii*, but higher concentrations of anti-inflammatory cytokines (IL-4 and IL-10), suggesting that *S. boulardii* has a protective effect by reducing the pro-inflammatory response. In addition, Lee *et al.*⁽³⁷⁾ observed that treatment of HT-29 cells with TNF- α and IL-1 β increased CXCL-8 concentrations in a murine model of trinitrobenzene sulphonic acid-induced colitis, whereas the effect was inhibited by the administration of *S. boulardii* through a decrease in the concentrations of inflammatory cytokines (CXCL-8, IL-1 β , TNF- α and inducible NO synthase). These studies clearly support our findings of

anti-inflammatory effects of *S. boulardii* on 5-FU-induced intestinal mucositis.

Another hypothesis for the beneficial effects of treatment with *S. boulardii* on intestinal mucositis induced by 5-FU was based on decreased apoptosis. We demonstrated that treatment with *S. boulardii* prevents an increase in apoptosis in intestinal crypt cells in the jejunum and ileum induced by 5-FU. Studies have demonstrated that 5-FU chemotherapy increases the number of apoptotic cells in mouse intestinal crypt^(38,39) and the mechanisms involved in chemotherapy-mediated induction of small-intestinal cell apoptosis are associated with the presence of pro-inflammatory cytokines such as TNF- α and IL-1 β ⁽⁴⁰⁾.

Moreover, Soares *et al.*⁽¹³⁾ found 5-FU-induced intestinal mucositis to be associated with delayed gastric emptying/intestinal transit of liquids and with hypercontractility of the deep muscle of the stomach and duodenum in both the inflammatory and post-inflammatory phases. Patients receiving anticancer therapy commonly experience gastrointestinal symptoms, especially dyspepsia, dysphagia and diarrhoea⁽⁴¹⁾, which are sometimes referred to as cancer-associated dyspepsia syndrome.

In the present study, *S. boulardii* reversed 5-FU-induced changes in gastrointestinal function, enhancing intestinal transit and gastric emptying and decreasing retention in the distal bowel segment, which may in part account for the observed attenuation of diarrhoea and weight loss. In parallel, the permeability of the small intestine of 5-FU-treated mice was significantly affected. The lactulose:mannitol excretion rate was significantly reduced by 5-FU treatment. A study has suggested that a reduction in mannitol absorption is related to the reduced surface area of intestinal mucosa and that increased lactulose absorption indicates a leaky gut⁽⁴²⁾. This finding is interesting because several authors have shown that the loss of integrity of the intestinal epithelial barrier can lead to bacterial translocation with the development of a systemic inflammatory response^(29,43,44). Reinforcing our findings, Garcia Vilela *et al.*⁽⁴⁵⁾ demonstrated that patients with inflammatory bowel disease present a significant change in mucosal integrity and that treatment with *S. boulardii* improves intestinal permeability in these patients. Thus, treatment with *S. boulardii* may be hypothesised to normalise bowel function by reducing inflammation associated with 5-FU-induced intestinal mucositis.

Few studies have evaluated the effects of probiotic bacteria on intestinal motility. Mediation of the relaxation of colonic motility by *Bifidobacterium*, *Lactobacillus* and *Streptococcus* has been suggested by one study⁽⁴⁶⁾. This mechanism could explain the observed attenuation of diarrhoea due to a reduction in stool frequency and restoration of the microbiota. Czerucka & Rampal⁽⁴⁷⁾ demonstrated that treatment with *S. boulardii* restored luminal electrolyte transport in cholera toxin-induced diarrhoea in the rabbit jejunum and suggested a mechanism involving cAMP-dependent chloride secretion. In addition, Budriesi *et al.*⁽⁴⁸⁾ used a mixture containing *Castanea sativa* and *S. boulardii* to induce anti-spasmodic and spasmolytic effects in segments of guinea pig intestinal smooth muscle that were contracted by carbachol, histamine,

KCl and BaCl₂, suggesting that the treatment's effect involved the inhibition of voltage-dependent Ca²⁺ channels.

According to McFarland⁽⁴⁹⁾, the protective effect of *S. boulardii* may involve different pathways classified as luminal, trophic or anti-inflammatory. These pathways include mechanisms such as maintenance of the integrity of the intestinal mucosa by preserving mucosal cell adhesion⁽⁵⁰⁾, neutralisation of bacterial virulence factors⁽⁵¹⁾ and increased immune response in the intestinal mucosa⁽⁵²⁾.

In conclusion, to our knowledge, this is the first study to evaluate the effect of administration of *S. boulardii* on the inflammatory and functional aspects of intestinal mucositis induced by 5-FU. Our findings will hopefully contribute to the discovery of novel probiotic-based treatments for gastrointestinal toxicity associated with anticancer therapy.

Acknowledgements

All sources of financial and material support were provided by a grant from CNPq and FUNCAP (Brazil). The funders had no role in study design, data collection and analysis, decision to publish or preparation of the manuscript.

The authors thank Maria S. F. França for excellent technical assistance in the experimental protocols.

The authors' contributions are as follows: P. F. C. J. and P. M. G. S. designed the study, conducted the study and data analysis and wrote the manuscript; A. A. L. conducted the study *in vivo* and data analysis; L. F. M. M., A. F. N., J. V. G. C., L. M. N. S., C. M. S., W. O. M., M. R. C. and A. X. F. conducted the study and data analysis; R. A. R. wrote the manuscript; M. H. L. P. S. designed the study and wrote the manuscript. All authors discussed, edited and approved the final version.

The authors declare that there are no conflicts of interest.

References

- Fuller R (1991) Probiotics in human medicine. *Gut* **32**, 439–442.
- Laudanno O, Vasconcelos L, Catalana J, *et al.* (2006) Anti-inflammatory effect of bioflora probiotic administered orally or subcutaneously with live or dead bacteria. *Dig Dis Sci* **51**, 2180–2183.
- Dieleman LA, Goerres MS, Arends A, *et al.* (2003) *Lactobacillus* GG prevents recurrence of colitis in HLA-B27 transgenic rats after antibiotic treatment. *Gut* **52**, 370–376.
- Jespersen L (2003) Occurrence and taxonomic characteristics of strains of *Saccharomyces cerevisiae* predominant in African indigenous fermented foods and beverages. *FEMS Yeast Res* **3**, 191–200.
- Buts JP & De Keyser N (2006) Effects of *Saccharomyces boulardii* on intestinal mucosa. *Dig Dis Sci* **51**, 1485–1492.
- Buts JP, Stilmant C, Bernasconi P, *et al.* (2008) Characterization of α,α -trehalase released in the intestinal lumen by the probiotic *Saccharomyces boulardii*. *Scand J Gastroenterol* **43**, 1489–1496.
- Sezer A, Usta U & Cicin I (2009) The effect of *Saccharomyces boulardii* on reducing irinotecan-induced intestinal mucositis and diarrhea. *Med Oncol* **26**, 350–357.
- Duncan M & Grant G (2003) Oral and intestinal mucositis – causes and possible treatments. *Aliment Pharmacol Ther* **18**, 853–874.

9. Longley DB, Harkin DP & Johnston PG (2003) 5-Fluorouracil: mechanisms of action and clinical strategies. *Nat Rev Cancer* **3**, 330–338.
10. Sonis ST (1998) Mucositis as a biological process: a new hypothesis for the development of chemotherapy-induced stomatotoxicity. *Oral Oncol* **34**, 39–43.
11. Baerg J, Murphy JJ, Anderson R, *et al.* (1999) Neutropenic enteropathy: a 10-year review. *J Pediatr Surg* **34**, 1068–1071.
12. Keefe DM, Gibson RJ & Hauer-Jensen M (2004) Gastrointestinal mucositis. *Semin Oncol Nurs* **20**, 38–47.
13. Soares PM, Mota JM, Gomes AS, *et al.* (2008) Gastrointestinal dysmotility in 5-fluorouracil-induced intestinal mucositis outlasts inflammatory process resolution. *Cancer Chemother Pharmacol* **63**, 91–98.
14. MacPherson BR & Pfeiffer CJ (1978) Experimental production of diffuse colitis in rats. *Digestion* **17**, 135–150.
15. Bradley PP, Christensen RD & Rothstein G (1982) Cellular and extracellular myeloperoxidase in pyogenic inflammation. *Blood* **60**, 618–622.
16. Sedlak J & Lindsay RH (1968) Estimation of total, protein-bound, and nonprotein sulfhydryl groups in tissue with Ellman's reagent. *Anal Biochem* **25**, 192–205.
17. Chen SM, Swilley S, Bell R, *et al.* (2000) Lead induced alterations in nitrite and nitrate levels in different regions of the rat brain. *Comp Biochem Physiol C Toxicol Pharmacol* **125**, 315–323.
18. Reynell PC & Spray GH (1958) Chemical gastroenteritis in the rat. *Gastroenterology* **34**, 867–873.
19. Lima AA, Silva TM, Gifoni AM, *et al.* (1997) Mucosal injury and disruption of intestinal barrier function in HIV-infected individuals with and without diarrhea and cryptosporidiosis in northeast Brazil. *Am J Gastroenterol* **92**, 1861–1866.
20. Pearson AD, Eastham EJ, Laker MF, *et al.* (1982) Intestinal permeability in children with Crohn's disease and coeliac disease. *Br Med J (Clin Res Ed)* **285**, 20–21.
21. Deitch EA (1990) Intestinal permeability is increased in burn patients shortly after injury. *Surgery* **107**, 411–416.
22. Sonis ST, Elting LS, Keefe D, *et al.* (2004) Perspectives on cancer therapy-induced mucosal injury: pathogenesis, measurement, epidemiology, and consequences for patients. *Cancer* **100**, 1995–2025.
23. Rubenstein EB, Peterson DE, Schubert M, *et al.* (2004) Clinical practice guidelines for the prevention and treatment of cancer therapy-induced oral and gastrointestinal mucositis. *Cancer* **100**, 2026–2046.
24. Edens HA, Levi BP, Jaye DL, *et al.* (2002) Neutrophil transepithelial migration: evidence for sequential, contact-dependent signaling events and enhanced paracellular permeability independent of transjunctional migration. *J Immunol* **169**, 476–486.
25. Lima V, Brito GA, Cunha FQ, *et al.* (2005) Effects of the tumour necrosis factor- α inhibitors pentoxifylline and thalidomide in short-term experimental oral mucositis in hamsters. *Eur J Oral Sci* **113**, 210–217.
26. Carneiro-Filho BA, Oria RB, Wood Rea K, *et al.* (2004) Alanylglutamine hastens morphologic recovery from 5-fluorouracil-induced mucositis in mice. *Nutrition* **20**, 934–941.
27. Petschow BW, Carter DL & Hutton GD (1993) Influence of orally administered epidermal growth factor on normal and damaged intestinal mucosa in rats. *J Pediatr Gastroenterol Nutr* **17**, 49–58.
28. Orazi A, Du X, Yang Z, *et al.* (1996) Interleukin-11 prevents apoptosis and accelerates recovery of small intestinal mucosa in mice treated with combined chemotherapy and radiation. *Lab Invest* **75**, 33–42.
29. Prisciandaro LD, Geier MS, Butler RN, *et al.* (2011) Probiotic factors partially improve parameters of 5-fluorouracil-induced intestinal mucositis in rats. *Cancer Biol Ther* **11**, 671–677.
30. Smith CL, Geier MS, Yazbeck R, *et al.* (2008) *Lactobacillus fermentum* BR11 and fructo-oligosaccharide partially reduce jejunal inflammation in a model of intestinal mucositis in rats. *Nutr Cancer* **60**, 757–767.
31. Girard P, Coppe MC, Pansart Y, *et al.* (2010) Gastroprotective effect of *Saccharomyces boulardii* in a rat model of ibuprofen-induced gastric ulcer. *Pharmacology* **85**, 188–193.
32. Wu X, Vallance BA, Boyer L, *et al.* (2008) *Saccharomyces boulardii* ameliorates *Citrobacter rodentium*-induced colitis through actions on bacterial virulence factors. *Am J Physiol Gastrointest Liver Physiol* **294**, G295–G306.
33. Canonici A, Siret C, Pellegrino E, *et al.* (2011) *Saccharomyces boulardii* improves intestinal cell restitution through activation of the $\alpha 2\beta 1$ integrin collagen receptor. *PLoS ONE* **6**, e18427.
34. Melo ML, Brito GA, Soares RC, *et al.* (2008) Role of cytokines (TNF- α , IL-1 β and KC) in the pathogenesis of CPT-11-induced intestinal mucositis in mice: effect of pentoxifylline and thalidomide. *Cancer Chemother Pharmacol* **61**, 775–784.
35. Soares PM, Lima-Junior RC, Mota JM, *et al.* (2010) Role of platelet-activating factor in the pathogenesis of 5-fluorouracil-induced intestinal mucositis in mice. *Cancer Chemother Pharmacol* **68**, 713–720.
36. Fidan I, Kalkanci A, Yesilyurt E, *et al.* (2009) Effects of *Saccharomyces boulardii* on cytokine secretion from intraepithelial lymphocytes infected by *Escherichia coli* and *Candida albicans*. *Mycoses* **52**, 29–34.
37. Lee SK, Kim YW, Chi SG, *et al.* (2009) The effect of *Saccharomyces boulardii* on human colon cells and inflammation in rats with trinitrobenzene sulfonic acid-induced colitis. *Dig Dis Sci* **54**, 255–263.
38. Wu ZQ, Han XD, Wang Y, *et al.* (2011) Interleukin-1 receptor antagonist reduced apoptosis and attenuated intestinal mucositis in a 5-fluorouracil chemotherapy model in mice. *Cancer Chemother Pharmacol* **68**, 87–96.
39. Yasuda M, Kato S, Yamanaka N, *et al.* (2012) Potential role of the NADPH oxidase NOX1 in the pathogenesis of 5-fluorouracil-induced intestinal mucositis in mice. *Am J Physiol Gastrointest Liver Physiol* **302**, G1133–G1142.
40. Sonis ST (2004) The pathobiology of mucositis. *Nat Rev Cancer* **4**, 277–284.
41. Riezzo G, Clemente C, Leo S, *et al.* (2005) The role of electrogastronomy and gastrointestinal hormones in chemotherapy-related dyspeptic symptoms. *J Gastroenterol* **40**, 1107–1115.
42. Hollander D (1999) Intestinal permeability, leaky gut, and intestinal disorders. *Curr Gastroenterol Rep* **1**, 410–416.
43. van Vliet MJ, Harmsen HJ, de Bont ES, *et al.* (2010) The role of intestinal microbiota in the development and severity of chemotherapy-induced mucositis. *PLoS Pathog* **6**, e1000879.
44. Wardill HR & Bowen JM (2013) Chemotherapy-induced mucosal barrier dysfunction: an updated review on the role of intestinal tight junctions. *Curr Opin Support Palliat Care* **7**, 155–161.
45. Garcia Vilela E, De Lourdes De Abreu Ferrari M, Oswaldo Da Gama Torres H, *et al.* (2008) Influence of *Saccharomyces boulardii* on the intestinal permeability of patients with Crohn's disease in remission. *Scand J Gastroenterol* **43**, 842–848.



46. Massi M, Ioan P, Budriesi R, *et al.* (2006) Effects of probiotic bacteria on gastrointestinal motility in guinea-pig isolated tissue. *World J Gastroenterol* **12**, 5987–5994.
47. Czerucka D & Rampal P (2002) Experimental effects of *Saccharomyces boulardii* on diarrheal pathogens. *Microbes Infect* **4**, 733–739.
48. Budriesi R, Ioan P, Micucci M, *et al.* (2010) Stop Fitan: anti-spasmodic effect of natural extract of chestnut wood in guinea pig ileum and proximal colon smooth muscle. *J Med Food* **13**, 1104–1110.
49. McFarland LV (2010) Systematic review and meta-analysis of *Saccharomyces boulardii* in adult patients. *World J Gastroenterol* **16**, 2202–2222.
50. Rodrigues AC, Nardi RM, Bambirra EA, *et al.* (1996) Effect of *Saccharomyces boulardii* against experimental oral infection with *Salmonella typhimurium* and *Shigella flexneri* in conventional and gnotobiotic mice. *J Appl Bacteriol* **81**, 251–256.
51. Czerucka D, Dahan S, Mograbi B, *et al.* (2001) Implication of mitogen-activated protein kinases in T84 cell responses to enteropathogenic *Escherichia coli* infection. *Infect Immun* **69**, 1298–1305.
52. Brandao RL, Castro IM, Bambirra EA, *et al.* (1998) Intracellular signal triggered by cholera toxin in *Saccharomyces boulardii* and *Saccharomyces cerevisiae*. *Appl Environ Microbiol* **64**, 564–568.