

ENDOCRINE PRACTICE Rapid Electronic Article in Press

Rapid Electronic Articles in Press are preprinted manuscripts that have been reviewed and accepted for publication, but have yet to be edited, typeset and finalized. This version of the manuscript will be replaced with the final, published version after it has been published in the print edition of the journal. The final, published version may differ from this proof.

DOI:10.4158/EP12129.CO

© 2012 AACE.

Commentary

EP12129.CO

Unusual problems in the management of Hyperthyroid Graves' disease

Devin W. Steenkamp MD¹, Ana Junqueira MD¹, and Lewis E. Braverman MD¹

Running title: Management of hyperthyroid Grave's disease

From the ¹Division of Endocrinology, Diabetes and Nutrition, Boston Medical Center, Boston, Massachusetts.

Address correspondence to Devin W. Steenkamp MD, Boston Medical Center, Division of Endocrinology, Diabetes and Nutrition, 88 East Newton St, Evans 201, Boston, MA 02118

Email: devin.steenkamp@bmc.org

DOI:10.4158/EP12129.CO

Endocrine Practice © 2012 AACE.

Graves' disease is a common endocrine disorder and the various permutations inherent in its management are usually straightforward for the practicing endocrinologist. However, we recently saw a 22 year old female with active Graves' disease who displayed two striking and unusual features which significantly impacted her management.

The patient was diagnosed with the classic features of hyperthyroid Graves' disease with multiple symptoms and physical findings consistent with the diagnosis, including a very large, homogeneous 200-300g goiter with an audible bruit and moderate ophthalmopathy. She was treated with high doses of methimazole (MMI, 40mg daily) and atenolol (50mg daily) for over 10 weeks as an outpatient with no improvement in her thyroid function tests or clinical findings. Serum total T3 remained >800ng/dl (83-160ng/dl), total T4 >24 ng/dl (5.1-11.4 mcg/dl) and TSH <0.001mIU/L (0.35-4.9 mIU/L) after 2 months of therapy with MMI. Graves' disease almost always responds appropriately to high doses of MMI within 2 to 3 months of therapy.

She was a well educated college student who adhered to her medications, yet she remained clinically and biochemically thyrotoxic, with persistent tremor, palpitations, marked proximal muscle weakness, audible bruit, a huge goiter and markedly elevated peripheral thyroid hormone levels.

A complicating factor in her management was that a CT scan of her neck and chest with iodinated contrast was performed one day after starting MMI therapy as part of a work up for an anterior mediastinal mass, consistent with a markedly enlarged thymus.

A decision was made to admit her to the hospital to prepare her for a thyroidectomy given the large size of her gland, presence of ophthalmopathy and persistent hyperthyroidism. We had continued difficulty in lowering the thyroid hormone concentrations as an inpatient as well, despite high doses of dexamethasone (2-3mg twice daily), SSKI (100-150meq every 8 hours) and MMI(20mg every 12 hours.) Progressive liver function test abnormalities precluded our ability to titrate MMI upwards given the potential contribution of MMI to these abnormalities.

She underwent an uncomplicated thyroidectomy 8 days after admission with a mildly elevated total T3 concentration of 282ng/dl at the time of surgery. Her symptoms had improved markedly pre-operatively with her heart rate ranging between 84-92/min on the day before the surgery. The thyroid weighed 243g with the left lobe measuring 10 x 5 x 4cm, the right lobe measuring 10 x 6 x 4cm and the isthmus measuring 3 x 1.5 x 2cm. There were no nodules present. Microscopy was consistent with chronic Graves' disease with some hemorrhagic components present in the right lobe. She had an uneventful recovery period and a repeat CT of the thymus 2 months later revealed a significant decrease in its size (Figure 2)

The association between Graves' disease and benign thymic hyperplasia has been known since the first reported case in 1895 (1) although the mechanism remains poorly understood. Thyrotropin receptors (TSH-R) have been identified in thymus tissue in humans and it has been suggested that activation of the TSH-R by the thyroid stimulating IgG (TSI) may be causally related to the thymic enlargement associated with Graves' disease (2.)Others have postulated that the thymus may play a role in the initiation of the

hyperthyroidism through its immuno-modulatory function (3.) However, thymectomy in patients with Graves' disease has not led to remission of the hyperthyroidism, arguing against being a causative factor in hyperthyroidism (3.)

The differential diagnosis of an enlarged thymus includes malignant etiologies such as lymphoma, carcinoid tumor or thymus carcinoma. A single case of malignant thymoma in association with SIADH, myasthenia gravis and Graves' disease has been described (4.) Approximately one-third of patients with Graves' disease have microscopic abnormalities in the thymus resulting in modest growth, but the occurrence of massive thymus growth, as seen in the present patient, is rare (12.) Most patients with thymus hyperplasia in the setting of Graves' disease have regression in thymus size with appropriate treatment and restoration of euthyroidism. Thus, careful follow up and non-operative intervention should be done in patients with thymus enlargement and Graves' disease (5, 13)

The speed with which individual patients respond to thionamide therapy is variable and there are no well known predictors as to which patients will respond very rapidly or those who may take longer to respond. Hyperthyroidism has been described to be relatively more resistant to thionamide treatment in areas of iodine sufficiency and large intrathyroidal iodine stores (6) and the converse holds true in areas of iodine deficiency where patients have been observed to respond relatively rapidly (7.) Thionamide drugs inhibit TPO catalyzed iodination of thyroglobulin and large doses often lead to complete inhibition (8.) High intra-thyroidal iodine concentrations impair this inhibition although usually larger doses of the thionamide will overcome this

problem given that the drug is concentrated several fold in the thyroid (9.) Current water-soluble intravenous contrast agents are cleared from the plasma quickly. However, an increase in the total body iodine stores may persist for many months after the contrast load (14.) Euthyroid patients often tolerate the iodine load well and minor changes in TSH often resolve within a few days. The phenomenon of iodine induced thyrotoxicosis is thought to be uncommon in iodine sufficient regions so routine prophylactic treatment is probably not warranted but is more common in regions of marginal or low iodine intake. A recent nested case control study in the greater Boston area has reported that thyroid dysfunction following contrast agents is not as uncommon as is generally thought and our knowledge has been limited by prior studies of small sample size, limited follow up and the lack of adequate control groups (23.) Patients with nodular goiter are particularly susceptible to the effects of large doses of iodine with a decrease in serum TSH and increase in serum T3 observed in a group of 70 patients exposed to enteral contrast agents used for cholangiopancreatography (16.) These changes can be prevented by pre-medication with methimazole or perchlorate prior to the contrast load, and in the case of coronary artery catheterization, continued for 14 days (17.) In addition, in patients with differentiated thyroid cancer who had been treated with total thyroidectomy and radio-iodine who underwent CT scans with iodinated contrast for evaluation of metastases, urinary iodine levels returned to baseline within 1 month after contrast load (15.) However it is likely that urinary iodine levels will persist for a longer period of time when the thyroid is intact.

Do iodinated contrast agents lead to “resistance” to anti-thyroid medications? This issue remains controversial. In vitro studies support the concept of reduced efficacy of anti-thyroid drugs in the presence of excess iodide (21-22.) Higher environmental dietary iodide intake may reduce the response to MMI in patients with Graves’ disease (7.) An older clinical study in the rapid control of hyperthyroid Grave’s disease compared MMI alone with MMI plus SSKI and MMI plus sodium ipodate. It concluded that MMI alone was similar to MMI plus SSKI in the rapid control of hyperthyroidism. MMI plus sodium ipodate was superior to the other two treatment approaches suggesting that iodine may not have any role in leading to resistance to the thionamide therapy. (24) A more recent clinical study concluded that combined treatment with MMI and oral potassium iodide tablets improved Graves’ disease in the short term and did not lead to worsening hyperthyroidism or thionamide resistance (20.) It should be noted that in all these studies antithyroid drugs and iodine were given simultaneously and definitive conclusions are difficult to ascertain.

Patients with severe Graves’ disease have been reported to improve rapidly to clinical euthyroidism within a few days when admitted to hospital and treated with a combination of agents including thionamides, B blockers and potent inhibitors of the deiodination of T4 to T3 such as dexamethasone and iopanoic acid (10). The latter is no longer available for clinical use in the U.S but is still available in Europe, Asia and South America. Iopanoic acid is an iodine rich oral radiographic contrast agent with close to 70% iodine content by weight used in cholecystography (11.) It is a potent inhibitor of both thyroid hormone syntheses and release and peripheral conversion of T4 to T3 via

inhibition of type I 5'-deiodinase activity. A single center series of 17 severely thyrotoxic patients with large goiters treated with this regimen were all clinically euthyroid at the time of thyroidectomy (10.) In the majority of patients in this series the total T₃ concentrations had returned to the normal range after 4 days of treatment. Only two patients still had slightly elevated serum total T₃ concentrations at the time of surgery. The other 15 patients had total T₃ levels well within the normal range. The total T₃ concentrations in our patient remained elevated much longer than would have been anticipated with similar aggressive treatment. Inorganic iodide, as sole therapy, in the form of saturated solution of potassium iodide (SSKI) with 35 to 50mg iodide per drop or as Lugol's solution (8mg iodide per drop) are beneficial in many patients with thyrotoxicosis. However the effects are often transient as many patients escape from the inhibitory effects within a few weeks (25.) These agents are primarily used as adjunctive agents to thionamide therapy in thyroid storm or as additive pre-operative agents which reduce the vascularity of the thyroid gland in patients who have already received anti thyroid drug therapy. (19)

We suggest that the massive iodine load at the time of the initial imaging study, in association with her very large and hyperplastic thyroid contributed to the failure of anti-thyroid drug therapy due to the decreased ability of the medication to suppress new thyroid hormone synthesis in the presence of vastly increased thyroid hormone and iodine stores.

These two unusual complications of Graves' disease highlight the complexity of management in some patients and should give clinicians pause before considering iodide

enhanced imaging studies in patients with active thyrotoxicosis. Goiter, thyrotoxicosis and iodinated contrast agents are strange bedfellows. Our reliance on these imaging studies may have un-anticipated consequences for our patients.

DISCLOSURES

None.

REFERENCES

1. **Halsted WS.** The significance of the thymus gland in Graves' disease. *Bull Johns Hopkins Hosp.* 1914;25:223-234.
2. **Murakami M, Hosoi Y, Negishi T, et al.** Thymic hyperplasia in patients with Graves' disease. Identification of thyrotropin receptors in human thymus. *J Clin Invest.* 1996;98:2228-2234
3. **Van Herle AJ, Chopra IJ.** Thymic hyperplasia in Graves' disease. *J Clin Endocrinol Metab.* 1971;32:140-146.
4. **Lee BW, Ihm SH, Shin HS, et al.** Malignant thymoma associated with myasthenia gravis, Graves' disease, and SIADH. *Intern Med.* 2008;47:1009-1012.
5. **Yacoub A, Gaitonde DY, Wood JC.** Thymic hyperplasia and graves disease: Management of anterior mediastinal masses in patients with Graves' disease. *Endo Pract.* 2009;15:534-539.
6. **Solomon BL, Evaul JE, Burman KD, et al.** Remission rates with antithyroid drug therapy: continuing influence of iodine intake? *Ann Intern Med* 1987;107:510-512.
7. **Azizi F.** Environmental iodine intake affects the response to methimazole in patients with diffuse toxic goiter. *J Clin Endocrinol Metab*1985;61:374-377.
8. **Engler H, Taurog A, Luthy C, et al.** Reversible and irreversible inhibition of thyroid peroxidase-catalyzed iodination by thioethylene drugs. *Endocrinology* 1983;112:86-95.

9. **Dalan R, Leow MKS, Ng DCE.** High iodine (substrate) turnover Graves' disease: the intriguing rapid responder variant of thyrotoxicosis. *Ann Clin Biochem.* 2008;45:612-615.
10. **Panzer C, Beazley R, Braverman L.** Rapid preoperative preparation for severe hyperthyroid Graves' disease. *J Clin Endocrinol Metab.* 2004;89:2142-2144.
11. **Maglint DT, Torres WE, Laufer I.** 1991 Oral cholecystography in contemporary gallstone imaging: a review. *Radiology.* 1991;178:49-58.
12. **Michie W, Gunn A.** The thyroid, the thymus and autoimmunity. *Br J Clin Pract* 1966;20:9-13.
13. **Popoveniuc G, Sharma M, Devdhar M, et al.** Graves' disease and thymic hyperplasia: the relationship of thymic volume to thyroid function. *Thyroid.* 2010;20:1015-1018.
14. **Amdur RJ, Mazzaferri EL.** Intravenous iodinated contrast effects iodine uptake for months. In: *Essentials of thyroid cancer management.* 1st ed. New York, NY: Springer. 2005, 211-213.
15. **Padovani R, Kasamatsu TS, Nakabashi CDC et al.** One Month is Sufficient for Urinary Iodine to Return to its Baseline Value after the Use of Water Soluble Iodinated Contrast Agents in Post-Thyroidectomy Patients Requiring Radioiodine Therapy. *Thyroid.* [Epub June 6, 2012].
16. **Fassbender WJ, Vogel C, Doppl W, et al.** Thyroid function, thyroid immunoglobulin status, and urinary iodide excretion after enteral contrast agent administration by endoscopic retrograde cholangiopancreatography. *Endoscopy* 2011;33:245.

17. **Nolte W, Muller R, Siggelkow H, et al.** Prophylactic application of thyrostatic drugs during excessive iodide exposure in euthyroid patients with thyroid autonomy: a randomized study. *Eur J Endocrinol* 1996;134:337.
19. **Chang DCS, Wheeler MH, Woodcock JP, et al.** The effect of pre-operative Lugol's iodine on thyroid blood flow in patients with Graves' hyperthyroidism. *Surgery* 1987;102:1055.
20. **Takata K, Nobuyuki A, Sumihisa K, et al.** Benefit of short-term iodide supplementation to antithyroid drug treatment of thyrotoxicosis due to Graves' disease. *Clinical Endocrinology*. 2010;72:845-850.
21. **Taurog, A.** The mechanism of action of the thioureyline antithyroid drugs. *Endocrinology*. 1976;98:1031-1046.
22. **Hashizume K, Akasu F, Takazawa K, et al.** The inhibitory effect of acute administration of excess iodide on the formation of adenosine 3', 5'-monophosphate induced by thyrotropin in mouse thyroid lobes. *Endocrinology*, 1976;99:1463-1468.
23. **Rhee CM, Bhan I, Alexander EK, Brunelli SM.** Association between iodinated contrast media exposure and incident hyperthyroidism and hypothyroidism. *Arch Intern Med*. 2012;172:153-159.
24. **Roti E, Robuschi G, Gardini E et al.** Comparison of methimazole, methimazole and sodium ipodate, and methimazole and saturated solution of potassium iodide in the early treatment of hyperthyroid Graves' disease. *Clin Endocrinol (Oxf)*. 1988;28:305-314.

25. Emerson CH, Anderson AJ, Howard WJ, et al. Serum thyroxine and triiodothyronine concentrations during iodide treatment of hyperthyroidism. *J Clin Endocrinol Metab.* 1975;40:33-36.

Figures 1-4.

Coronal and axial CT images of the chest showing marked thymic enlargement pre-operatively with decrease in thymic size 2 months post operatively consistent with improvement in thymic hyperplasia with treatment of the underlying Grave's disease.

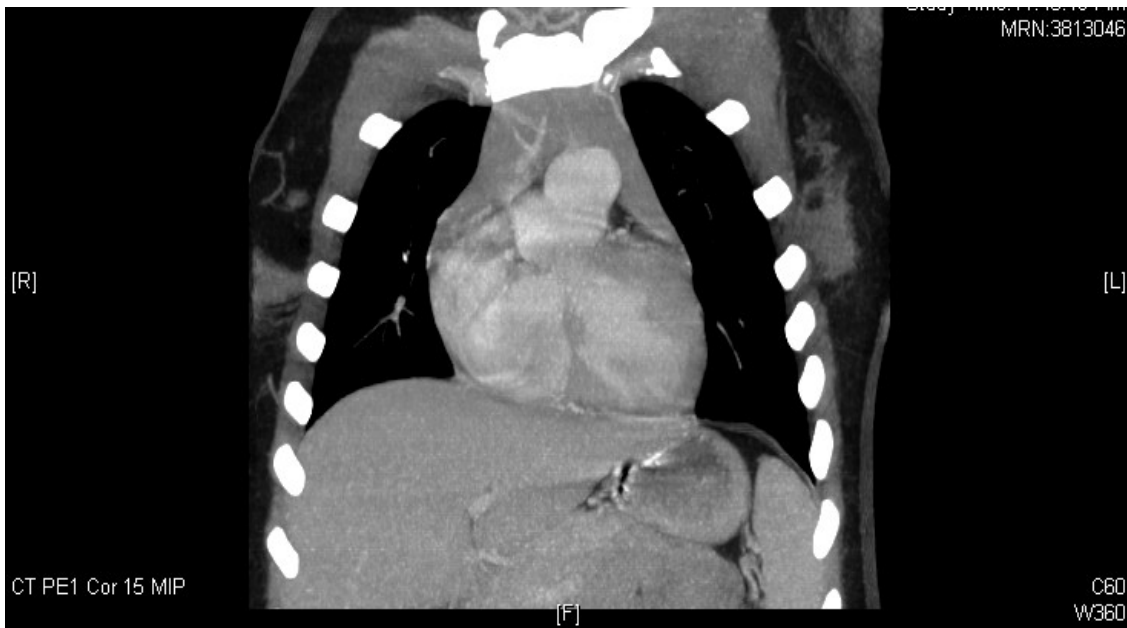


FIG 1. Pre-operative CT chest coronal view

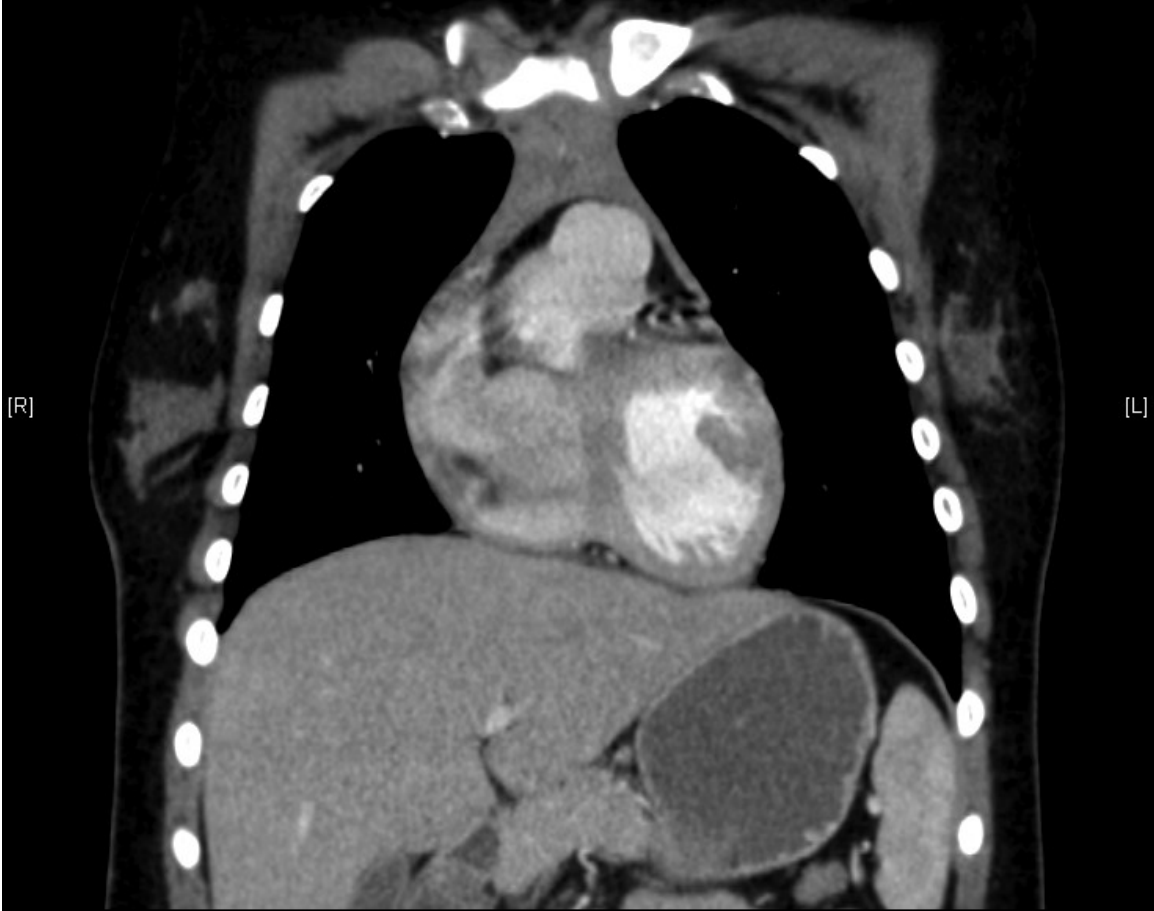

FIG 2. Post-operative CT chest coronal view

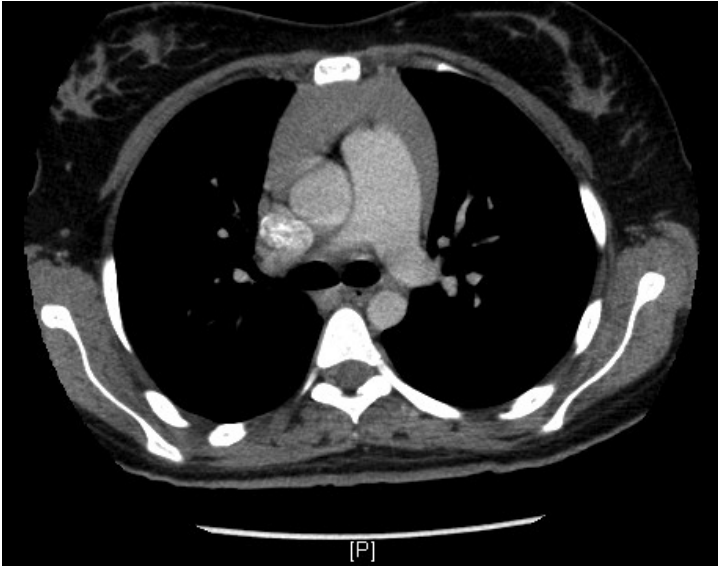


FIG 3. Pre-operative CT chest axial view

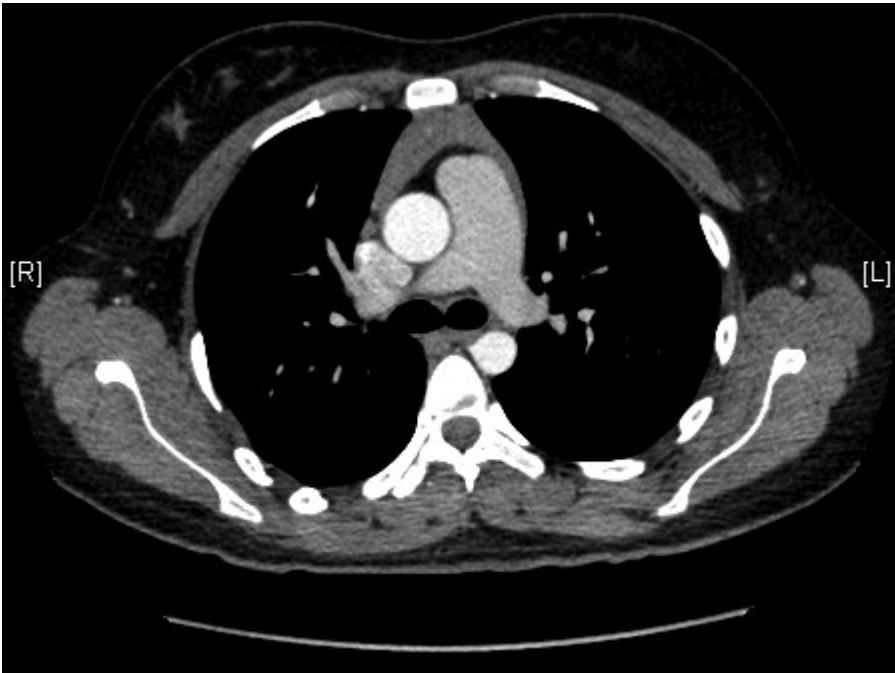


FIG 4. Post-operative CT chest axial view