

Tay-Sachs disease: case report

Doença de Tay-Sachs: relato de caso

André Tigre Lima¹. Ricardo Evangelista Marrocos de Aragão^{1,2}. Igor Costa Menezes³. Pedro Marques de Mesquita Filho³. Lívia Studart de Menezes¹. Rafael Jorge Alves de Alcântara¹.

1 Hospital Universitário Walter Cantídio (HUWC), Fortaleza, Ceará, Brasil. 2 Universidade Federal do Ceará (UFC), Fortaleza, Ceará, Brasil. 3 Fundação Leiria de Andrade (FLA), Fortaleza, Ceará, Brasil.

ABSTRACT

Objectives: Report a case of Tay-Sachs disease. **Methods:** A complete ophthalmologic examination, retinography and blood dosage of hexosaminidase A (EHA) activity were performed. **Results:** A one year and seven months old male with a history of generalized tonic-clonic seizures, with delayed neuropsychomotor development from the eighth month of life. At the ophthalmologic examination the patient did not fix or follow objects, with bilateral horizontal nystagmus. The funduscopy revealed an image of “cherry-red spot” in the macula in both eyes. Dosage of EHA activity confirmed diagnosis of Tay-Sachs disease. **Conclusion:** Tay-Sachs Disease is a genetic disease with an autosomal recessive inheritance pattern characterized by deficiency of EHA activity, leading to the accumulation of sphingolipids in neuronal cells that results in progressive neurological dysfunction. In the retina, there is deposition in the ganglion cells, resulting in the appearance of cherry-red spot macula. There is no curative treatment, aiming at the therapy, only the clinical support in the patient.

Keywords: Tay-Sachs disease. Hexosaminidase A. Sphingolipids.

RESUMO

Objetivos: relatar um caso de doença de Tay-Sachs. **Métodos:** realizado exame oftalmológico completo, retinografia e dosagem sanguínea da atividade da enzima hexosaminidase A (EHA). **Resultados:** paciente do sexo masculino, um ano e sete meses de idade, com histórico de convulsões tônico-clônicas. Observado atraso do desenvolvimento neuropsicomotor a partir do oitavo mês de vida. Ao exame oftalmológico, paciente não fixava o olhar e nem seguia objetos, apresentando nistagmo bilateral horizontal. A fundoscopia, revelou imagem de mácula em cereja em ambos os olhos. Dosada a atividade da EHA confirmou o diagnóstico de doença de Tay-Sachs. **Conclusão:** doença de Tay-Sachs é uma doença genética com padrão de herança autossômica recessiva caracterizada pela deficiência da atividade EHA, levando ao acúmulo de esfingolipídios em células neuronais que resulta em uma disfunção neurológica progressiva. Na retina, ocorre o depósito nas células ganglionares, originando o aspecto em mácula em cereja. Não existe um tratamento curativo, visando a terapêutica, apenas, o suporte clínico no paciente.

Palavras-chave: Doença de Tay-Sachs. Hexosaminidase A. Esfingolipídeos.

Corresponding author: Ricardo Evangelista Marrocos de Aragão, Rua Osvaldo Cruz, 2335, Dionísio Torres, Fortaleza, Ceará. CEP: 60125-151. Telephone: +55 85 99137-9313. E-mail: ricardomarrocos@yahoo.com

Conflict of interests: The authors have no conflicts of interest to declare.

Received: 24 Nov 2019; Revised: 12 Jan 2020; Accepted: 12 Jan 2020.

INTRODUCTION

Tay-Sachs disease is a neurodegenerative disorder that results in accumulation of a glycosphingolipid (ganglioside GM2) especially in neurons. Its pathophysiology is a partial or total quantitative defect of the enzyme hexosaminidase A, a genetic condition determined by an autosomal recessive pattern.¹ In the first months of life there is minimal or no clinical abnormality, being only identified in the electronic microscopy of the brain and the retina.²

Signs and symptoms begin around the 5th month of life characterized by progressive psychomotor retardation, megaencephaly, cherry-red spot, retinal injury, blindness, deafness, paralysis and death between the 3rd and 5th year of life. The ophthalmological changes have been described since 1881 by Warren Tay and shows an unaltered optic nerve, pale-whitish macula well-delimited with a notoriously hyperchromic center in red-brown color. This color contrast draws attention and defines the injury in "cherry-red spot".³

The histological changes that characterize the background in cherry-red spot are due to the intense accumulation of glycosphingolipid in the macula's ganglion cells, which leaves a pale-whitish appearance. On the other hand, foveal depression, which does not contain ganglion cells, maintains the normal retina's red appearance.⁴

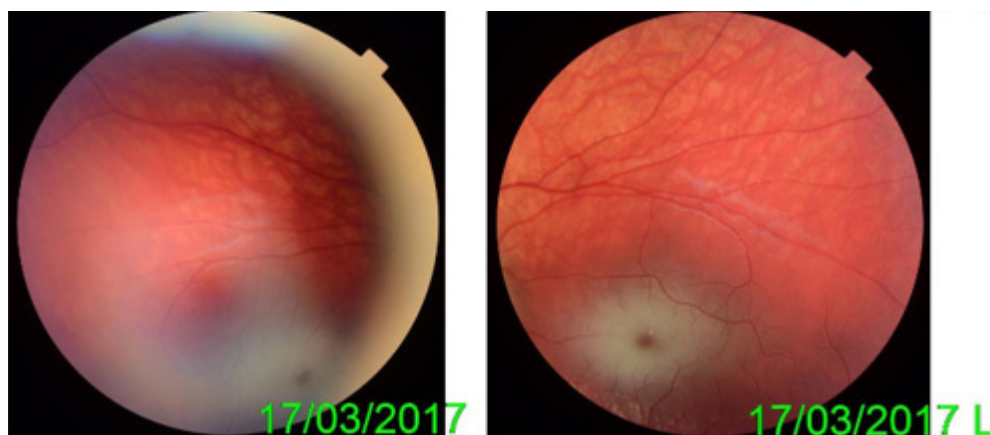
It is important to emphasize that cherry-red spot injury is not pathognomonic of Tay-Sachs disease. Some other metabolic disorders in which there are lipid deposits also have the same fundus, such as generalized gangliosidosis, Niemann-Pick disease, and Fabry disease.

CASE-REPORT

A male patient 1 year and 8 months old, came to us referred from the pediatric clinic due to seizures to investigate systemic disease. He was born at a gestational age of 40 weeks with no intercurrent; parents were healthy and second cousins. Mother stated that when the baby was eight months old, it stopped holding its head and was weak to move its limbs, by that time it was also observed that he stopped looking and following objects. Since then, the weakness has become more evident. The patient began to present seizures that became more frequent and lasting, reaching 3 to 4 episodes a day.

Psychomotor retardation, muscle weakness, generalized hyperreflexia, was observed in examination. In ophthalmologic exam, patient did not follow objects or fixate the eyes. Ophthalmoscopy revealed chalk-white macular areas with a "cherry-red spot" in the fovea of both eyes (Figure 1). A deficiency of hexosaminidase A in the serum disclosed the diagnosis of Tay-Sachs disease.

Figure 1. Retinography revealed an image of "cherry-red spot" in the macula in both eyes.



DISCUSSION

Tay-Sachs disease is due to the accumulation of GM2 trihexosylceramide secondary to the defect of hexosaminidase A enzyme, caused by mutation.⁵ It accumulates predominantly in retinal ganglion cells whereby retina becomes with "chalk-white" coloration.³ This is typically present early in the disease, is a clue in the diagnosis, thus, it has been detected even in the fetal stage. Progressive loss of neurological function, hyperirritability, and progressive weakness, loss of motors and intellectual skills at the end of the first year are observed. They may crawl but never walk. The natural course

leads to a decerebrate, vegetative stage by second to fourth year of life and death.

A juvenile form of Tay-sachs disease exists, with late onset and slower course but with a similar constellation of signs. An adult form is also described with ataxia, dysarthria, muscle weakness, and dementia. However, in that form, no "cherry-red" spot is seen.³

The diagnosis of Tay-Sachs disease is confirmed by assaying for the activity of individual hexosaminidase isoenzymes in serum.

Hexosaminidase A deficiency is inherited in the autosomal recessive pattern. Thus, the parents must be heterozygous, since they would not survive to reproductive age in the condition of recessive homozygotes. During conception, therefore, the offspring have a 25% chance of being affected, a 50% chance of being an asymptomatic carrier of the recessive allele and 25% of being neither affected nor the carrier. Couples with a positive history of children with Tay-Sachs should undergo genetic counseling because there is a high risk of this fatal disease repeats in offspring.¹

There are already reliable genetic screening tests for the detection of carriers in high-risk populations, such as in Jewish communities, helping to prevent primary disease.⁶

REFERENCES

1. Kaback MM, Desnick RJ. Hexosaminidase A deficiency [Internet]. In: Adam MP, Ardinger HH, Pagon RA, Wallace SE, Bean LJ, Stephens K, et al., editors. GeneReviews®. Seattle (WA): University of Washington; 1999 [Updated 2011 Aug 11; cited 2019 Nov 21]. Available from: <https://www.ncbi.nlm.nih.gov/sites/books/NBK1218>.
2. Cogan DG, Kuwabara T, Kolodny E, Driscoll S. Gangliosidoses and the fetal retina. *Ophthalmology*. 1984;91(5):508-12.
3. Koller C. Rare and fatal disease of infancy. *Trans Am Ophthalmol Soc*. 1896;7:661-8.
4. Aragão RE, Ramos RM, Pereira FB, Bezerra AF, Fernandes DN. "Cherry red spot" in a patient with Tay-Sachs disease: case report. *Arq Bras Oftalmol* [Internet]. 2009 [cited 2019 Nov 21];72(4):537-9.

Currently, Tay-Sachs disease treatment is signs and symptoms control and clinical support, although enzyme replacement therapies have been introduced for several lysosomal storage, no effective treatment is available. It is important that the patient has adequate hydric and nutritional intake, early identification of secondary infections and airway protection. Seizures should be managed pharmacologically with antiepileptics. As the disease progresses, seizures become more frequent, necessitating changes in drug doses.

Trials with intravenous enzyme replacement therapy were not effective because they could not cross the blood-brain barrier. *In vivo* studies with rats using intracranial injections containing recombinant viral vectors of hexosaminidase A producing genes are showing promise for the future.⁷

Available from: http://www.scielo.br/scielo.php?script=sci_arttext&pid=S000427492009000400019&lng=en.

5. Cotlier E. Symposium: the eye and inborn metabolic disorders. Concluding remarks. *Ophthalmology*. 1978;85(10):1004-43.
6. Lew RM, Burnett L, Proos AL, Barlow-Stewart K, Delatycki MB, Bankier A, et al. Ashkenazi Jewish population screening for Tay-Sachs disease: the international and Australian experience. *J Paediatr Child Health*. 2015;51(3):271-9.
7. Cachón-González MB, Wang SZ, McNair R, Bradley J, Lunn D, Ziegler R, et al. Gene transfer corrects acute GM2 gangliosidosis--potential therapeutic contribution of perivascular enzyme flow. *Mol Ther*. 2012;20(8):1489-1500.

Como citar:

Lima AT, Aragão RE, Menezes IC, Mesquita PM, Menezes LS, Alcântara RJ. Tay-Sachs disease: case report. *Rev Med UFC*. 2020 jul-set;60(3):48-50.